



A Student's Guide to ECG Interpretation

Ajit Kumar Pradhan

Technician

SCB MCH ,Cuttack

At – Patulisahi po Kesharpur ,Nayagarh,Odisha

Abstract:

Since its inception, the electrocardiogram (ECG) has been an essential tool in medicine. The ECG is more than a mere tracing of cardiac electrical activity; it can detect and diagnose various pathologies including arrhythmias, pericardial and myocardial disease, electrolyte disturbances, and pulmonary disease. The ECG is a simple, non-invasive, rapid, and cost-effective diagnostic tool in medicine; however, its clinical utility relies on the accuracy of its interpretation. Computer ECG analysis has become so widespread and relied upon that ECG literacy among clinicians is waning. With recent technological advances, the application of artificial intelligence-augmented ECG (AI-ECG) algorithms has demonstrated the potential to risk stratify, diagnose, and even interpret ECGs—all of which can have a tremendous impact on patient care and clinical workflow. In this review, we examine (i) the utility and importance of the ECG in clinical practice, (ii) the accuracy and limitations of current ECG interpretation methods, (iii) existing challenges in ECG education, and (iv) the potential use of AI-ECG algorithms for comprehensive ECG interpretation

- Index Terms - *Electrocardiogram (ECG), ECG Clinical Interpretation, ECG wave's interval & segments.*

I. INTRODUCTION

The electrocardiogram (ECG) is one of the simplest and oldest cardiac investigations available, yet it can provide a wealth of useful information and remains an essential part of the assessment of cardiac patients.

With modern machines, surface ECGs are quick and easy to obtain at the bedside and are based on relatively simple electrophysiological concepts. However junior doctors often find them difficult to interpret.

This is the first in a short series of articles that aim to:

- Help readers understand and interpret ECG recordings.
- Reduce some of the anxiety juniors often experience when faced with an ECG.

Table of contents

Chapter - I

Study of General Anatomy and Physiology of Human Heart

- *Introduction to the Human Heart*
- *Position of Heart in Human Body*
- *The Function of Heart*

Chapter - II

- *Types of Circulation*
- *Structure of the Human Heart*
- *Chambers of the Heart*
- *Blood Vessels*
- *Valves*
- *The electricity of the heart*

Chapter - III

ECG (ELECTROCARDIOGRAM)

- *History of ECG.*
- *Understanding the physiology*
- *Formation of the ECG*
- *ECG Leads*
- *Normal Chest Lead ECG*
- *Paediatric ECG*
- *Determination of Electrical Axis*
- *Abnormalities of qrs axis*
- *Heart Rate*
- *The rhythm of the heart*
- *The ECG 'Rule of Fours'*
- *7 step approach to ECG rhythm analysis*

Chapter - IV

ECG wave's interval & segments.

- *P Wave*
 - **P Wave**
 - **Absent p wave**
 - **Inverted p wave**
 - **Changing p wave morphology**
 - **Tall p wave**
 - **Broad p wave**
- *PR Interval*
- *The Q Wave*
 - **Q waves in different leads**
 - **Pathological Q Waves**
 - **Differential Diagnosis**
 - **Loss of normal Q waves**

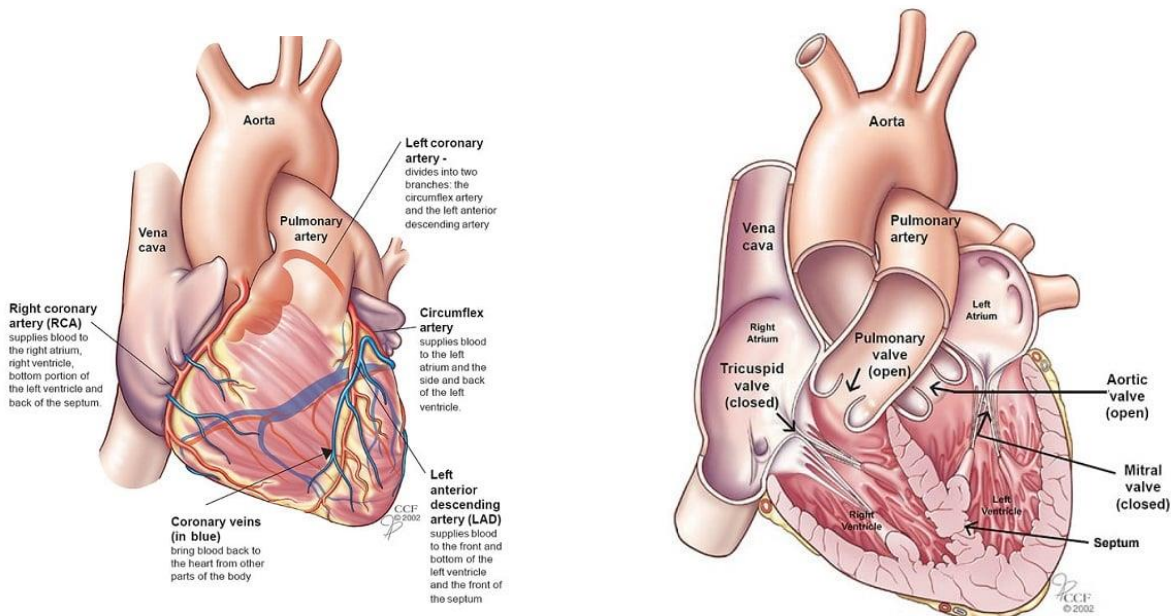
- **The R Wave**
 - R wave Overview
 - Abnormalities of the R wave
 - Dominant R wave in V1
 - Dominant R wave in aVR
 - Poor R wave progression
- **S Wave**
- **QRS Complex**
- **(J Wave)**
- **T wave Overview**
- **TP Segment**
- **QT Interval**
- **The ST Segment**
- **U wave**
- **Epsilon Wave**

Chapter - V

- **ECG Clinical Interpretation**
- **Some cardiac diseases & terminology**

Human Heart

The heart is a muscular structure that is situated in the front of the chest. It pumps blood all through the body in a process called circulation. Apart from the heart, the blood vessels and blood as a unit constitute the cardiovascular system.



Introduction to the Human Heart

The human heart is one of the most important organs responsible for sustaining life. It is a muscular organ with four chambers. The size of the heart is the size of about a clenched fist.

The human heart functions throughout a person's lifespan and is one of the most robust and hardest working muscles in the human body.

Besides humans, most other animals also possess a heart that pumps blood throughout their bodies. Even invertebrates such as grasshoppers possess a heart like pumping organ, though they do not function the same way a human heart does.

Position of Heart in Human Body

The human heart is located between the lungs in the thoracic cavity, slightly towards the left of the sternum (breastbone). It is derived from the embryonic mesodermal germ layer.

The Function of Heart

The function of the heart in any organism is to maintain a constant flow of blood throughout the body. This replenishes oxygen and circulates nutrients among the cells and tissues.

Following are the main functions of the heart:

- One of the primary functions of the human heart is to pump blood throughout the body.
- Blood delivers oxygen, hormones, glucose and other components to various parts of the body, including the human heart.
- The heart also ensures that adequate blood pressure is maintained in the body

There are two types of circulation within the body, namely pulmonary circulation and systemic circulation.

Types of Circulation

- **Pulmonary circulation** is a portion of circulation responsible for **carrying deoxygenated blood away from the heart**, to the lungs and then bringing oxygenated blood back to the heart.
- **Systemic circulation** is another portion of circulation where the **oxygenated blood is pumped from the heart to every organ** and tissue in the body, and deoxygenated blood comes back again to the heart.

Now, the heart itself is a muscle and therefore, it needs a constant supply of oxygenated blood. This is where another type of circulation comes into play, the coronary circulation.

- **Coronary circulation** is an essential portion of the circulation, where oxygenated blood is supplied to the heart. This is important as the heart is responsible for supplying blood throughout the body.
- Moreover, organs like the brain need a steady flow of fresh, oxygenated blood to ensure functionality.

In a nutshell, the **circulatory system** plays a vital role in supplying oxygen, and nutrients and removing carbon dioxide and other wastes from the body. Let us gain a deeper insight into the various anatomical structures of the heart:

Structure of the Human Heart

The human heart is about the size of a human fist and is divided into four chambers, namely **two ventricles and two atria**. The ventricles are the chambers that pump blood and the atrium are the chambers that receive blood. Among these both the right atrium and ventricle make up the "right heart," and the left atrium and ventricle make up the "left heart." The structure of the heart also houses the biggest artery in the body – **the aorta**.

The right and the left region of the heart are separated by a wall of muscle called the septum. The right ventricle pumps the blood to the lungs for re-oxygenation through the pulmonary arteries. The right semilunar valves close and prevent the blood from flowing back into the heart. Then, the oxygenated blood is received by the left atrium from the lungs via the pulmonary veins. Read on to explore more about the structure of the heart.

External Structure of Heart

One of the very first structures which can be observed when the external structure of the heart is viewed is the pericardium.

Pericardium

The human heart is situated to the left of the chest and is enclosed within a fluid-filled cavity described as the pericardial cavity. The walls and lining of the pericardial cavity are made up of a membrane known as the pericardium.

The pericardium is a fibre membrane found as an external covering around the heart. It protects the heart by producing a serous fluid, which serves to lubricate the heart and prevent friction between the surrounding organs. Apart from the lubrication, the pericardium also helps by holding the heart in its position and by maintaining a hollow space for the heart to expand itself when it is full. The pericardium has two exclusive layers—

- **Visceral Layer:** It directly covers the outside of the heart.
- **Parietal Layer:** It forms a sac around the outer region of the heart that contains the fluid in the pericardial cavity.

Structure of the Heart Wall

The heart wall is made up of 3 layers, namely:

- **Epicardium** – Epicardium is the outermost layer of the heart. It is composed of a thin-layered membrane that serves to lubricate and protect the outer section.

- **Myocardium** – This is a layer of muscle tissue and it constitutes the middle layer wall of the heart. It contributes to the thickness and is responsible for the pumping action.
- **Endocardium** – It is the innermost layer that lines the inner heart chambers and covers the heart valves. Furthermore, it prevents the blood from sticking to the inner walls, thereby preventing potentially fatal blood clots.

Internal Structure of Heart

The internal structure of the heart is rather intricate with several chambers and valves that control the flow of blood.

Chambers of the Heart

Vertebrate hearts can be classified based on the number of chambers present. For instance, most fish have two chambers, and reptiles and amphibians have three chambers. Avian and mammalian hearts consists of four chambers. Humans are mammals; hence, we have four chambers, namely:

- Left atrium
- Right atrium
- Left ventricle
- Right ventricle

Atria are thin and have less muscular walls and are smaller than ventricles. These are the blood-receiving chambers that are fed by the large veins.

Ventricles are larger and more muscular chambers responsible for pumping and pushing blood out into circulation. These are connected to larger arteries that deliver blood for circulation.

The right ventricle and right atrium are comparatively smaller than the left chambers. The walls consist of fewer muscles compared to the left portion, and the size difference is based on their functions. The blood originating from the right side flows through the pulmonary circulation, while blood arising from the left chambers is pumped throughout the body.

Blood Vessels

Your heart pumps blood through three types of blood vessels:

Arteries carry oxygen-rich blood from your heart to your body's tissues. The exception is your pulmonary arteries, which go to your lungs.

Veins carry oxygen-poor blood back to your heart.

Capillaries are small blood vessels where your body exchanges oxygen-rich and oxygen-poor blood.

Your heart receives nutrients through a network of coronary arteries. These arteries run along your heart's surface. They serve the heart itself.

Left coronary artery: Divides into two branches (the circumflex artery and the left anterior descending artery).

Circumflex artery: Supplies blood to the left atrium and the side and back of the left ventricle.

Left anterior descending artery (LAD): Supplies blood to the front and bottom of the left ventricle and the front of the septum.

Right coronary artery (RCA): Supplies blood to the right atrium, right ventricle, bottom portion of the left ventricle and back of the septum.

Valves

Your heart valves are like doors between your heart chambers. They open and close to allow blood to flow through.

The atrioventricular (AV) valves open between your upper and lower heart chambers. They include:

Tricuspid valve: Door between your right atrium and right ventricle.

Mitral valve: Door between your left atrium and left ventricle.

Semilunar (SL) valves open when blood flows out of your ventricles. They include:

Aortic valve: Opens when blood flows out of your left ventricle to your aorta (artery that carries oxygen-rich blood to your body).

Pulmonary valve: Opens when blood flows from your right ventricle to your pulmonary arteries (the only arteries that carry oxygen-poor blood to your lungs).

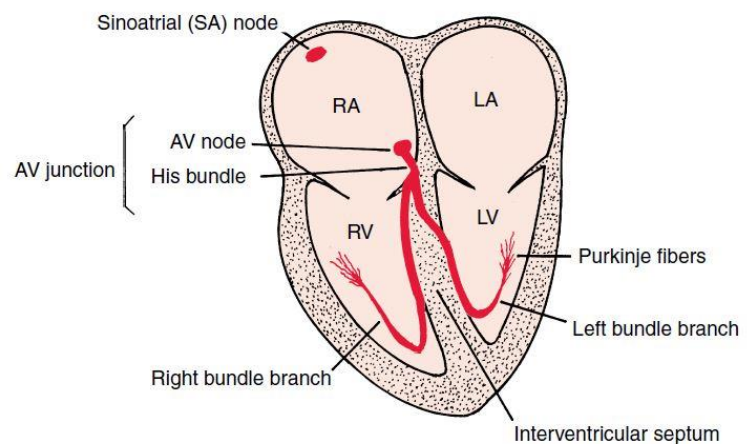
THE ELECTRICITY OF THE HEART

The contraction of any muscle is associated with electrical changes called 'depolarization', and these changes can be detected by electrodes attached to the surface of the body. Since all muscular contraction will be detected, the electrical changes associated with contraction of the heart muscle will only be clear if the patient is fully relaxed and no skeletal muscles are contracting. Although the heart has four chambers, from the electrical point of view it can be thought of as having only two, because the two atria contract together ('depolarization'), and then the two ventricles contract together.

THE WIRING DIAGRAM OF THE HEART

The electrical discharge for each cardiac cycle normally starts in a special area of the right atrium called the 'sinoatrial (SA) node'.

Depolarization then spreads through the atrial muscle fibres. There is a delay while depolarization spreads through another special area in the atrium, the 'atrioventricular node' (also called the 'AV node', or sometimes just 'the node'). Thereafter, the depolarization wave travels very rapidly down specialized conduction tissue, the 'bundle of His', which divides in the septum between the ventricles into right and left bundle branches. The left bundle branch itself divides into two. Within the mass of ventricular muscle, conduction spreads somewhat more slowly, through specialized tissue called 'Purkinje fibres'.



History of ECG.

The invention of the electrocardiograph by Dutch physiologist Willem Einthoven in 1902 gave physicians a powerful tool to help them diagnose various forms of heart disease, especially arrhythmias and acute myocardial infarction. The discovery of x-rays in 1895 and the invention of the electrocardiograph 7 years later inaugurated a new era in which various machines and technical procedures gradually replaced the physician's unaided senses and the stethoscope as the primary tools of cardiac diagnosis. These sophisticated new approaches provided objective information about the structure and function of the heart in health and disease. This review summarizes the origins and development of electrocardiography and addresses its role in defining cardiology as a specialty.

Understanding the physiology

The basic principle of the ECG is that stimulation of a muscle alters the electrical potential of the muscle fibres. Cardiac cells, unlike other cells, have a property known as automaticity, which is the capacity to spontaneously initiate impulses. These are then transmitted from cell to cell by gap junctions that connect cardiac cells to each other.

The electrical impulses spread through the muscle cells because of changes in ions between intracellular and extracellular fluid. This is referred to as action potential. The primary ions involved are potassium, sodium and calcium. The action potential is the potential for action created by the balance between electrical charges (positive and negative) of ions on either side of the cell membrane.

When the cells are in a resting state, the insides are negatively charged compared to the outsides. Membrane pumps act to maintain this electrical polarity (negative charge) of the cardiac cells. Contraction of the heart muscle is triggered by depolarisation, which causes the internal negative charge to be lost transiently.

However, following depolarisation, the cardiac cells return again to their resting charge, known as repolarisation.

These waves of depolarisation and repolarisation represent an electrical current and can be detected by placing electrodes on the surface of the body.² After the current has spread from the heart through the body, the changes are picked up by the ECG machine and the activity is recorded on previously sensitised paper. The ECG is therefore a graphic representation of the electrical activity in the heart. The current is transmitted across the ECG machine at the selected points of contact of the electrode with the body.

Formation of the ECG

Cardiac depolarisation begins from the SA node in the right atrium, causing it to contract. The impulse is transmitted from the right atrium to the left atrium, which then contracts. The first positive deflection seen on the ECG represents atrial depolarisation and is labelled the P wave. The normal P wave is < 0.08seconds (two small squares on the ECG paper) in duration.

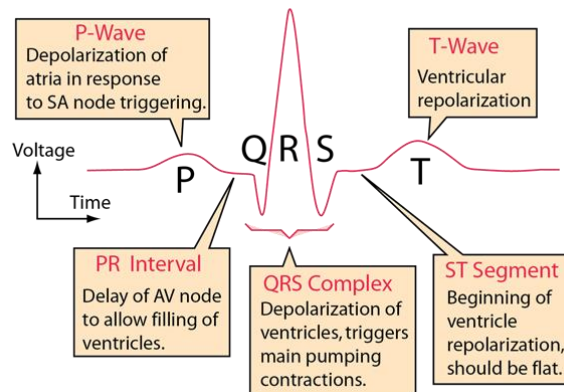
There is a short delay between atrial contraction and impulse conduction through the AV node. This period of delay is referred to as the PR interval. It is measured from the beginning of the P wave until the beginning of the R wave. During this time the ECG normally returns to the baseline, which is referred to as the isoelectric line. The PR interval is normally between 0.12-0.20 seconds.

The Q wave, caused by septal depolarisation, is the first negative deflection seen on the ECG after the P wave. A normal Q wave is less than one small square wide. A Q wave is not always apparent on the ECG. An enlarged Q wave is significant and indicative of abnormalities.

There is rapid impulse conduction through the bundle of his, the bundle branches, the fascicles and the purkinje fibres. The deflection seen on the ECG is strongly positive. Conduction spreads through the ventricles from the endocardium to the epicardium. The R wave is the first positive deflection of the QRS complex and the S wave is the first negative deflection after the R wave, seen below the isoelectric line. The normal QRS complex is < 0.12 seconds in duration. This is an indication of the speed of conduction of the ventricular impulses. The ECG graph should return again to the isoelectric line after the S wave.

The final waveform seen on the ECG is the T wave. The T wave represents repolarisation of the ventricular muscle. This simply corresponds with relaxation of the muscle prior to the next electrical impulse. The T wave should be positive and should be of no greater duration than 0.16 seconds. The duration between the S and T waves (ST segment) is not significant. It is important that the ECG graph returns to the isoelectric line between the S wave and the T wave. An abnormal isoelectric line between the S and T waves provides clues to problems with depolarisation and should be noted and reported

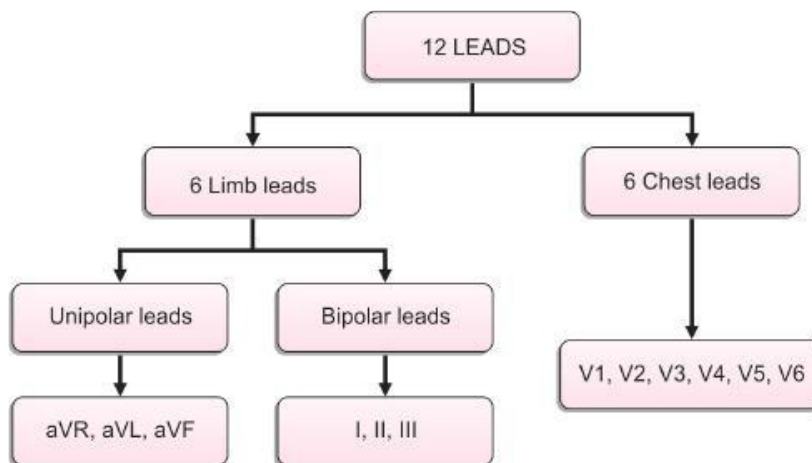
1. SA node 60 – 100 bpm
2. Atrial cells 55 – 60 bpm
3. AV node 45 – 50 bpm
4. Bundle of His 40 – 45 bpm
5. Bundle branch 40 – 45 bpm
6. Purkinje cells 35 – 40 bpm
7. Myocardial cells 30 – 35 bpm



ECG Leads

There are twelve leads consisting of six limb leads (I, II, III, aVR, aVL and aVF) and six chest leads (V1–V6). The limb leads consists of standard bipolar (I, II and III) and augmented (aVR, aVL and aVF) leads. The bipolar leads were so named because they record the difference in electrical voltage between two extremities.

For example:



R	Red
L	Yellow
N	Black
F	Green
C1	White/Red
C2	White/Yellow
C3	White/Green
C4	White/Brown
C5	White/Black
C6	White/Violet

Lead I: Records the difference in voltage between the left arm and the right arm electrodes.

Lead II: The difference in voltage between the left leg and the right arm electrodes.

Lead III: The difference in voltage between the left leg and the left arm electrodes.

In augmented limb leads, the abbreviation ‘a’ refers to augmented; V to voltage; R, L and F to right arm, left arm and left foot (leg) respectively. They record the electrical voltage of corresponding extremity

Placement of limb leads:

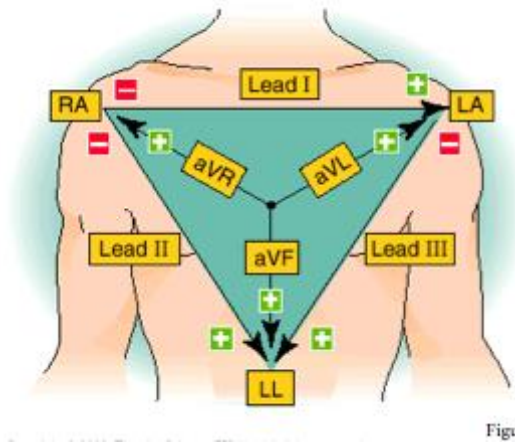
- Right arm (RA)
- Left arm (LA)
- Right leg (RL)

Left leg (LL)

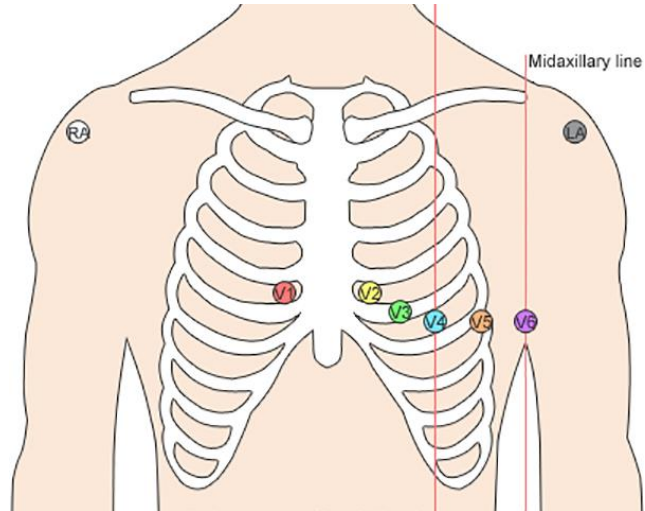
Placement of Chest Leads

- V1- fourth intercostal space at the right sternal border
- V2- fourth intercostal space at the left sternal border
- V4- fifth intercostal space at mid clavicular line
- V3- midway between V2 and V4
- V5- at the same horizontal level as V4 in the anterior axillary line
- V6- at the same horizontal level as V4 in the mid axillary line.

A EINTHOVEN'S TRIANGLE

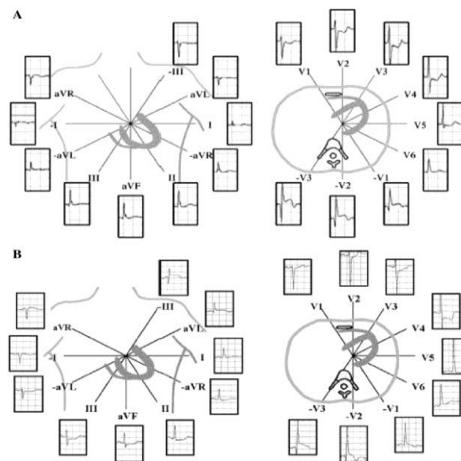
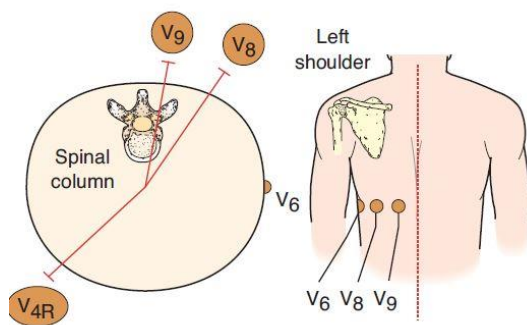


Figure



THE 15-LEAD ECG

Areas of the heart that are not well visualized by the six chest leads include the wall of the right ventricle and the posterior wall of the left ventricle. A 15-lead ECG, which includes the standard 12 leads plus leads V_{4R}, V₈, and V₉, increases the chance of detecting an MI in these areas



18-LEAD ECG

The diagnosis of STEMI by synthesized 18-lead ECG is useful to identify the site of infarction in patients with infarction of the right ventricular wall (supplied by the RCA) or posterior wall of the left ventricle (supplied by the LCX), which often fail to be diagnosed by the standard 12-lead ECG.

24-LEAD ECG

The 24-lead ECG is a display of the standard 12-lead ECG as both the classical positive leads and their negative (inverted) counterparts. Leads +V1, +V2, +V3, +V4, +V5, and +V6 and their inverted counterparts are used to generate a "clock-face display" for the transverse plane.

Posterior Leads

Posterior leads are helpful in suspected posterior myocardial infarction. They are performed by placing V4, V5 and V6 electrodes in the same intercostal space, but continuing into the patient's back.

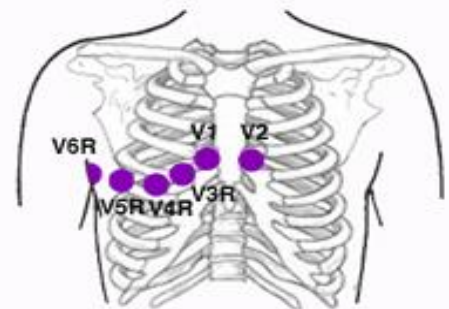
- **V7:** in the fifth intercostal space and the left posterior axillary line.
- **V8:** at the same level as electrode V6 and the midscapular line (tip of the scapula).
- **V9:** at the same level as electrodes V6 the left paravertebral line.

Right-Side Leads:

Right-side leads are recommended in patients with inferior myocardial infarct, when right ventricular infarct is suspected.

They are also useful in patients with dextrocardia, *situs inversus* or in some cases of congenital heart disease


- **V1:** same as normal location.
- **V2:** same as normal location.
- **V3R:** on a line midway between electrodes V1 and V4R.
- **V4R:** in the fifth **right** intercostal space, in the mid-clavicular line
- **V5R:** in the fifth **right** intercostal space, in the left anterior axillary line.
- **V6R:** at the same level as electrodes V4R and V5R, in the left midaxillary line.



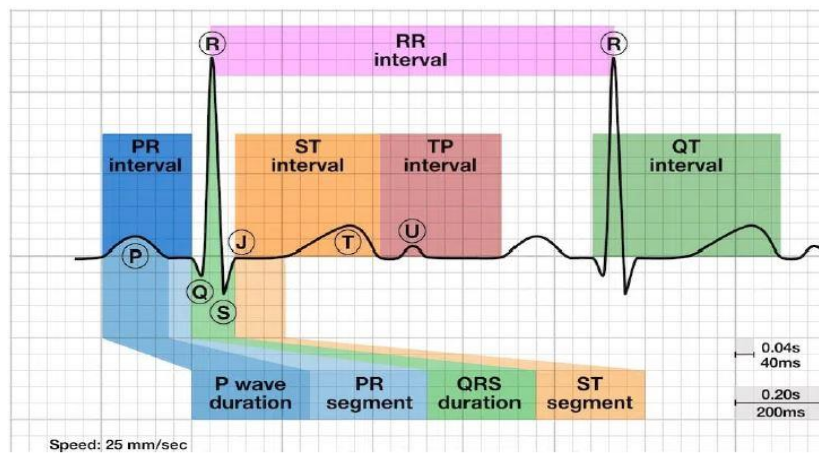
ECG Basics - Posterior ECG leads

ST elevation greater than 0.5 mm in leads V7-9 is diagnostic of a Posterior wall MI

<p>Posterior ECG lead placement</p> <p>Figure 1 - Posterior ECG lead placement</p>	<p>V7 Left posterior axillary line: in the same horizontal plane as V4-V6</p> <p>V8 Tip of the left midscapula: in the same horizontal plane as V7-V9</p> <p>V9 Left paravertebral region: in the same horizontal plane as V4-V6</p> <p>V1-V3 Should remain unchanged from standard 12-lead ECG</p>	<p>12-Lead acute Posterior wall MI</p> <p>Figure 2 - Correct labeling of the Posterior ECG</p>
<p>Posterior MI is suggestive by the following changes in V1-V3:</p> <ul style="list-style-type: none"> *Horizontal ST depression *Tall, broad R waves (>30ms) *Upright T waves *Dominant R wave (R/S ratio >1) in V2 	<p>Please note that V6 is a good reference point for the horizontal placement of the posterior electrodes V7-9.</p> <p>If you don't have access to a 15 or 18 lead ECG machine, then leave V1-3 in their normal position and use V4-6, these leads will then become V7-9.</p>	<p>Tips for recording Posterior Electrocardiograms (ECG's)</p> <ul style="list-style-type: none"> * Arm and leg electrodes remain unchanged * Lead cable V4 connects to V7 * Lead cable V5 connects to V8 * Lead cable V6 connects to V9 * REMEMBER to handwrite POSTERIOR LEADS on the ECG * Relabel V4-V6 on the printout V7-9 (Figure-2). * Findings may be very subtle, only 0.5 mm. * Always double check your lead placement to confirmed your in the correct anatomical spaces.



V1–V2	Septal wall
V3–V4	Anterior wall
I, aVL, V5-V6	Lateral wall
II, III, Avf	Inferior wall



Wave: A positive or negative deflection from baseline that indicates a specific electrical event. The waves on an ECG include the P wave, Q wave, R wave, S wave, T wave and U wave.

Interval: The time between two specific ECG events. The intervals commonly measured on an ECG include the PR interval, QRS interval (also called QRS duration), QT interval and RR interval.

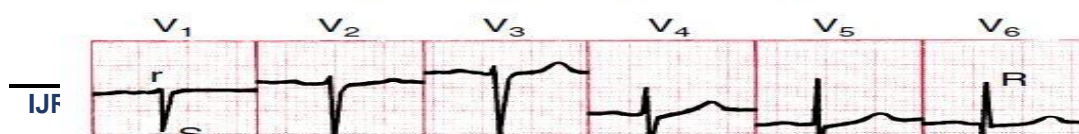
Segment: The length between two specific points on an ECG that are supposed to be at the baseline amplitude (not negative or positive). The segments on an ECG include the PR segment, ST segment and TP segment.

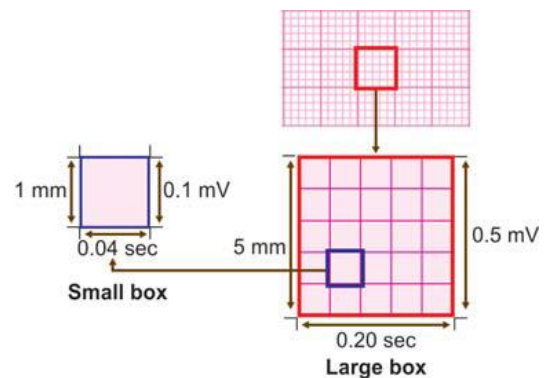
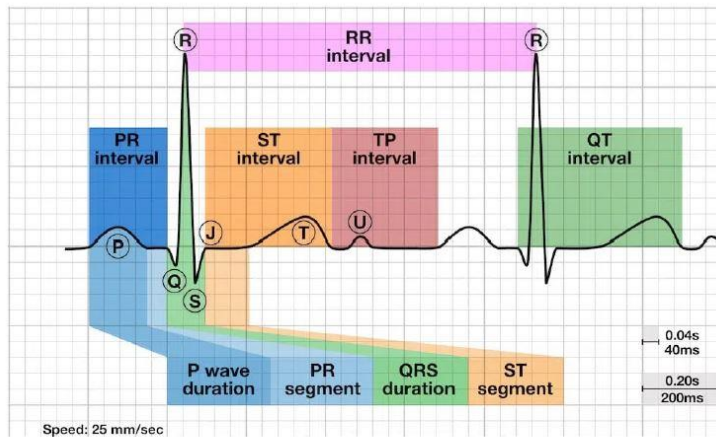
Complex: The combination of multiple waves grouped together. The only main complex on an ECG is the QRS complex.

Point: There is only one point on an ECG termed the J point, which is where the QRS complex ends and the ST segment begins. The main part of an ECG contains a P wave, QRS complex and T wave. Each will be explained individually in this tutorial, as will each segment and interval.

The P wave indicates atrial depolarization. The QRS complex consists of a Q wave, R wave and S wave and represents ventricular depolarization. The T wave comes after the QRS complex and indicates ventricular repolarisation.

Normal Chest Lead ECG





1. P wave:

- It represents **atrial depolarisation**
- Normal duration: < 0.12 s (< 120ms or 3 small squares)
- upright in leads I, aVF and V3 - V6
- polarity is positive in leads I, II, aVF and V4 - V6; diphasic in leads V1 and V3; negative in aVR
- shape is generally smooth, not notched or peaked

2 Q wave:

- Q wave is less than 2 small squares
- Deeper Q waves (>2 mm) may be seen in leads III and aVR as a normal variant
- Under normal circumstances, Q waves are not seen in the right-sided leads (V1-3)

3 R wave:

- The R wave represents early ventricular depolarisation
- The height of the R wave is variable and increases progressively across the precordial leads; it is usually <27 mm in leads V5 and V6. The R wave in lead V6, however, is often smaller than the R wave in V5, since the V6 electrode is further from the left ventricle

4. PR interval:

- The **PR interval** is the time from the onset of the P wave to the start of the QRS complex. It reflects conduction through the AV node.
- The normal PR interval is between 120 – 200 ms (0.12-0.20s) in duration (three to five small squares).

5. QRS complex:

- Duration less than or equal to 0.12 seconds 3 small , amplitude greater than 0.5 mV 1 big in at least one standard lead, and greater than 1.0 mV in at least one precordial lead. Upper limit of normal amplitude is 2.5 - 3.0 mV.
- small septal Q waves in I, aVL, V5 and V6 (duration less than or equal to 0.04 seconds; amplitude less than 1/3 of the amplitude of the R wave in the same lead).
- represented by a positive deflection with a large, upright R in leads I, II, V4 - V6 and a negative deflection with a large, deep S in aVR, V1 and V2
- in general, proceeding from V1 to V6, the R waves get taller while the S waves get smaller. At V3 or V4, these waves are usually equal. This is called the transitional zone.

6. ST segment:

- isoelectric, slanting upwards to the T wave in the normal ECG
- can be slightly elevated (up to 2.0 mm in some precordial leads)
- never normally depressed greater than 0.5 mm in any lead

7. T wave:

- T wave deflection should be in the same direction as the QRS complex in at least 5 of the 6 limb leads
- normally rounded and asymmetrical, with a more gradual ascent than descent
- should be upright in leads V2 - V6, inverted in aVR
- amplitude of at least 0.2 mV in leads V3 and V4 and at least 0.1 mV in leads V5 and V6
- isolated T wave inversion in an asymptomatic adult is generally a normal variant

8 QT interval:

- Durations normally less than or equal to 0.40 seconds for males and 0.44 seconds for females.

9. QT Interval

- QTc is prolonged if > 440ms in men or > 460ms in women
- QTc > 500 is associated with an increased risk of torsades de pointes
- QTc is abnormally short if < 350ms
- A useful rule of thumb is that a normal QT is less than half the preceding RR interval

10. U wave

- The U wave is a small (0.5 mm) deflection immediately following the T wave
- U wave is usually in the same direction as the T wave.
- U wave is best seen in leads V2 and V3

PAEDIATRIC ECG

NORMAL PAEDIATRIC ECG

- Newborn: 110 – 150 bpm
- 2 years: 85 – 125 bpm
- 4 years: 75 – 115 bpm
 - > 6 years: 60 – 100 bpm
- Apparent **right ventricular strain pattern**:
 - T wave inversions in V1-3 ("juvenile T-wave pattern")
 - Right axis deviation
 - Dominant R wave in V1
 - RSR' pattern in V1
- Marked sinus arrhythmia
- Short PR interval (< 120ms) and QRS duration (<80ms)
- Slightly peaked P waves (< 3mm in height is normal if ≤ 6 months)
- Slightly prolonged QTc (≤ 490ms in infants ≤ 6 months)
- Q waves in the inferior and left precordial leads

Normal QRS axis varies with age:

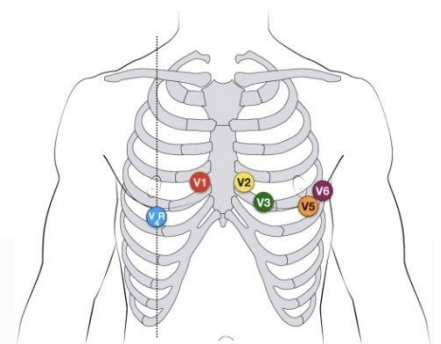
- 1 week – 1 month: + 110° (range +30° to +180°)
- 1 month – 3 months: + 70° (range +10° to +125°)
- 3 months – 3 years: + 60° (range +10° to +110°)
- Over 3 years: + 60° (range +20° to +120°)
- Adult: + 50° (range -30° to 105°)

Placement of paediatric ECG leads

In young children, the right ventricle normally extends to the right side of the sternum. To appropriately display right ventricular potentials, ECGs for children in the under five-year age group must include an alternate lead ('V4R') on the right side of the chest, at a point analogous to the left-sided V4.

Precordial leads:

- V1: 4th intercostal space, right sternal border
- V2: 4th intercostal space, left sternal border
- V3: midway between V2 and the placement of V4 in adults (5th intercostal space, left mid-clavicular line)



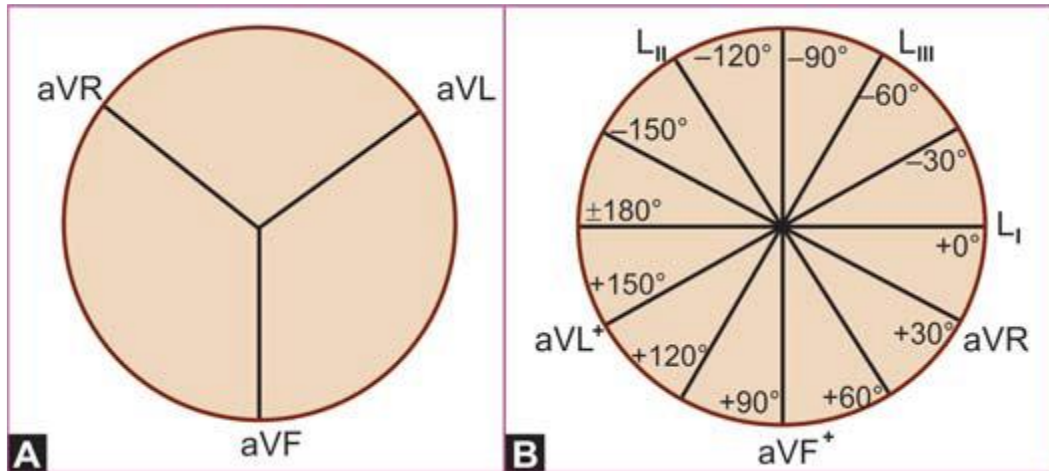
- **V4R:** 5th intercostal space, right mid-clavicular line. Use this lead for V4R, must label as such on ECG.
- V5: anterior axillary line, same horizontal plane as V4
- V6: mid-axillary line, same horizontal line as V4

Limb leads:

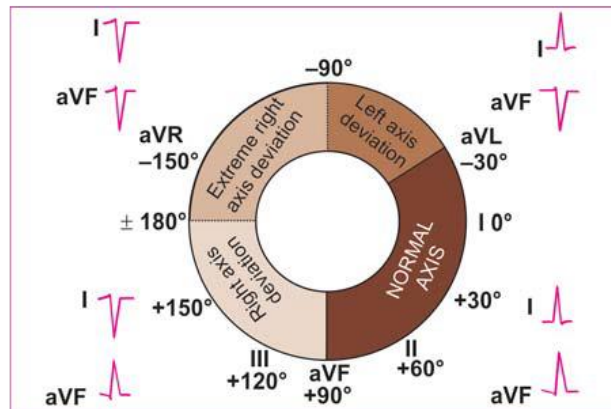
- Place on top part of arm or leg (less muscle interference)

Determination of Electrical Axis

During activation of the heart, the electrical forces or action potentials which have been generated, are propagated in various directions. These electrical forces can be picked up from the surface of the body by means of electrodes



A. The triaxial reference system from unipolar leads
 B. The hexaxial system from unipolar and limb leads



The normal QRS axis and axis deviation

Methods of ECG Axis Interpretation

There are several complementary approaches to estimating QRS axis, which are summarized below:

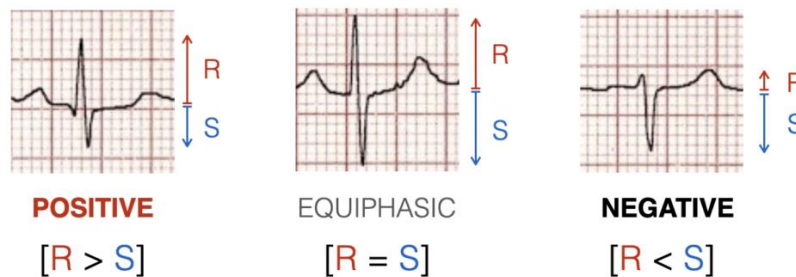
- **The Quadrant Method** – (Lead I and aVF)
- **Three Lead analysis** – (Lead I, Lead II and aVF)

- **Isoelectric Lead analysis**
- **Super SAM the Axis Man**

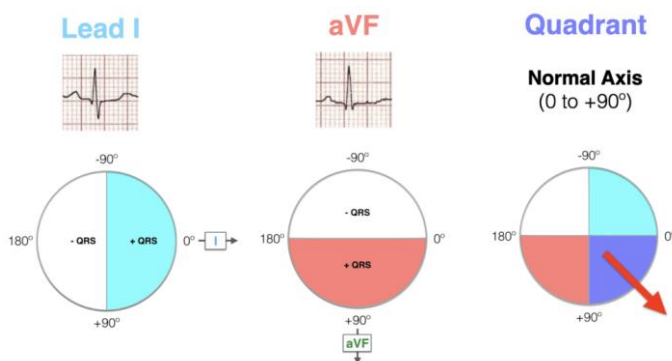
Method 1 – The Quadrant Method

The most efficient way to estimate axis is to look at **LEAD I** and **LEAD aVF**.

Examine the QRS complex in each lead and determine if it is Positive, Isoelectric (Equiphasic) or Negative:



- A **positive QRS** in **Lead I** puts the axis in roughly the same direction as lead I.
- A **positive QRS** in **Lead aVF** similarly aligns the axis with lead aVF.
- Combining both coloured areas – the quadrant of overlap determines the axis. So If Lead I and aVF are **both positive**, the axis is between 0° and +90° (i.e. normal axis).

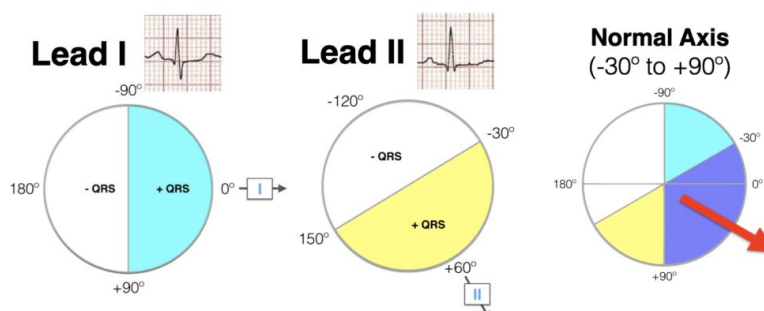


Lead I	Lead aVF	Quadrant	Axis
POSITIVE	POSITIVE		Normal Axis (0 to +90°)
POSITIVE	NEGATIVE		**Possible LAD (0 to -90°)
NEGATIVE	POSITIVE		RAD (+90° to 180°)
NEGATIVE	NEGATIVE		Extreme Axis (-90° to 180°)

Method 2: Three Lead analysis – (Lead I, Lead II and aVF)

Next we add in **Lead II** to the analysis of Lead I and aVF

- A **positive QRS** in **Lead I** puts the axis in roughly the same direction as lead I.
- A **positive QRS** in **Lead II** similarly aligns the axis with lead II.
- We can then combine both coloured areas and the area of overlap determines the axis. So If Lead I and II are **both positive**, the axis is between -30° and +90° (i.e. normal axis).

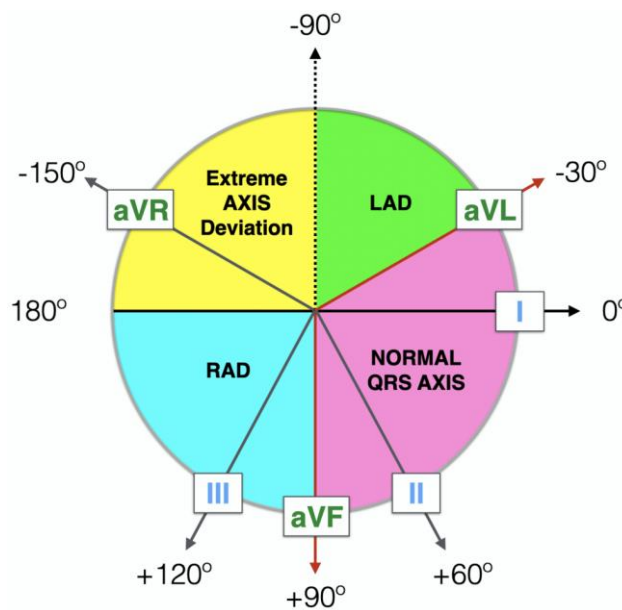


- The combined evaluation of Lead I, Lead II and aVF – allows rapid and accurate QRS assessment. The addition of Lead II can help determine pathological LAD from normal axis/physiological LAD
- **Note: Lead III or aVF** can *both* be used in three lead analysis

	Normal Axis (0 to +90°)	LAD PHYSIOLOGICAL (0 to -30°)	LAD PATHOLOGICAL (-30° to -90°)	RAD (90° to 180°)	Extreme Axis (-90° to -180°)	Indeterminate (?)
LEAD I	POSITIVE	POSITIVE	POSITIVE	NEGATIVE	NEGATIVE	EQUIPHASIC
LEAD II	POSITIVE	EQUIPHASIC	NEGATIVE	POSITIVE	NEGATIVE	EQUIPHASIC
LEAD III or aVF	POSITIVE	NEGATIVE	NEGATIVE	POSITIVE	NEGATIVE	EQUIPHASIC

Method 3 – The Isoelectric Lead

This method allows a more precise estimation of QRS axis, using the axis diagram below.



Key Principles

- If the QRS is **POSITIVE** in any given lead, the axis points in *roughly* the **same direction** as this lead.
- If the QRS is **NEGATIVE** in any given lead, the axis points in *roughly* the **opposite direction** to this lead.
- If the QRS is **ISOELECTRIC** (equiphasic) in any given lead (*positive deflection = negative deflection*), the axis is at 90° to this lead.

Step 1: Find the isoelectric lead. The isoelectric (equiphasic) lead is the frontal lead with **zero net amplitude**. This can be either:

- A biphasic QRS where R wave height = Q or S wave depth.
- A flat-line QRS with no discernible features.

Step 2: Find the positive leads.

- Look for the leads with the tallest R waves (or largest R/S ratios)

Step 3: Calculate the QRS axis.

- The QRS axis is at **90°** to the isoelectric lead, pointing **in the direction** of the positive leads.

ABNORMALITIES OF QRS AXIS

- Normal QRS axis -30° to +90°
- Right axis deviation +90° to +180°

Causes

- Thin tall built
- Chronic lung disease
- Pulmonary embolism
- Ostium secundum ASD
- Right ventricular hypertrophy
- Left posterior hemiblock
- Lateral wall infarction

- Left axis deviation -30° to -90°

Causes

- Obese stocky built
- WPW syndrome
- Cardiac pacing
- Ostium primum ASD
- Left ventricular hypertrophy
- Left anterior hemiblock
- Inferior wall infarction

- North-West QRS axis -90° to -180°

Causes

- Congenital heart disease
- Left ventricular aneurysm
- Synonyms
- Indeterminate QRS axis
- Extreme right axis deviation
- NO MAN'S LAND

Heart Rate

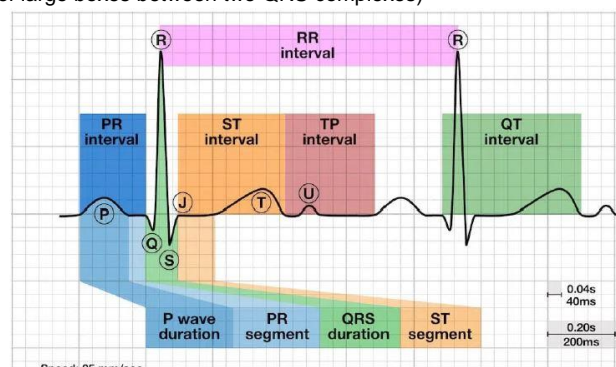
There are many ways to determine a patient's heart rate using ECG. One of the quickest ways is called the sequence method. To use the sequence method, find an R wave that lines up with one of the dark vertical lines on the ECG paper. If the next R wave appears on the next dark vertical line, it corresponds to heart rate of 300 beats a minute. The dark vertical lines correspond to 300, 150, 100, 75, 60, and 50 bpm. For example, if there are three large boxes between R waves, the patient's heart rate is 100 bpm.

There are more accurate ways to determine heart rate from ECG, but in life-saving scenarios, this method provides a quick estimate.

$$\text{Heart rate (beats per minute)} = 60 / (\text{the R-R interval in seconds}),$$

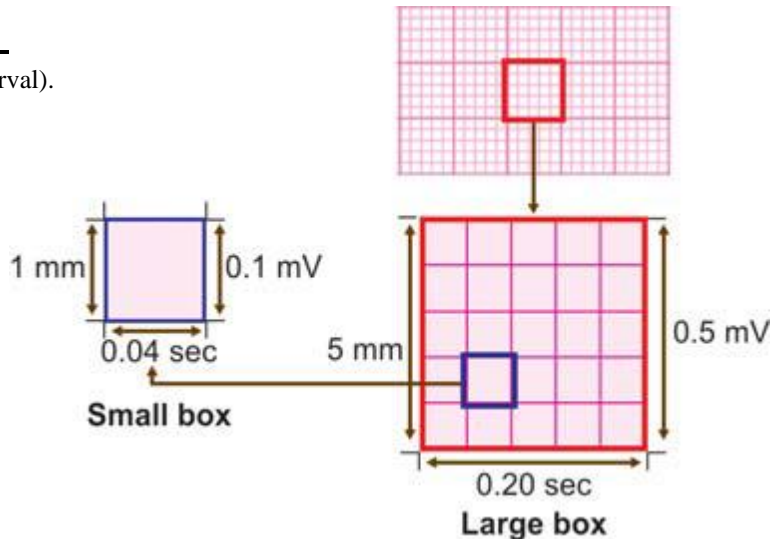
$$= 300 / (\text{the number of large boxes between two QRS complexes})$$

- Normal rate (HR 60-100)
- Bradycardia (HR < 60)
- Tachycardia (HR > 100)
- PR 0.12–0.21 sec
- PR prolongation ≥0.22 sec
- QRS < 0.12
- QRS axis -30° to +105°



QTc the corrected QT interval (calculated as $QT \div \sqrt{PI}$ interval).

It varies with age and gender, but is roughly <0.45 sec.



THE RHYTHM OF THE HEART

As we shall see later, electrical activation of the heart can sometimes begin in places other than the SA node. The word 'rhythm' is used to refer to the part of the heart which is controlling the activation sequence. The normal heart rhythm, with electrical activation beginning in the SA node, is called 'sinus rhythm'.

The ECG 'Rule of Fours'

- **Four Initial Features**
- **Four Waves**
- **Four Intervals**

The key is to read each ECG methodically, following the basic structure, looking at all leads, (and please please PLEASE try not to cheat and look at the computer interpretation...). So let's take a brief look at each of the above.

The FOUR INITIAL FEATURES to look for on an ECG

(1) HISTORY/ CLINICAL PICTURE

This is THE MOST IMPORTANT thing to look at on ANY ECG. Remember, an ECG is just like any other test, and should always be interpreted in the **clinical context**, perhaps even more so.

Simple things need to be recorded, like the name, age, time, patient symptoms (e.g. chest pain) and other clinical features.

Also do a quick check for lead placement errors:

- **Limb leads:** (a) check aVR for upside down P, QRS and T waves, (b) aVL and aVR should generally be mirror images.
- **Chest leads:** look for RS pattern in V1 – changing progressively to QR pattern in V6.

(2) RATE

- The normal value is between 60-100/min. Lower than this is bradycardia, higher is tachycardia.

(3) RHYTHM

- Is the rhythm sinus or is it another rhythm? If so, what?

(4) AXIS

- Discussion of "axis" is a whole other blog in itself, so don't get too hung up about it! The easiest way to learn is with 'SAM Super Axis Man'.

The FOUR WAVES (or complexes) on an ECG

(1) P WAVE

- Lead II is usually the best lead place to look at the P wave morphology.
- Observe the P-wave morphology e.g. in particular P pulmonale or P mitrale.

(2) QRS COMPLEXES (OR QRS "WAVES")

- Look in ALL leads for the presence of Q waves.
- Observe the QRS amplitude and look for QRS progression through the chest leads.

(3) T WAVES

- Look in ALL leads for T waves.
- Look for T wave inversion, T wave concordance or discordance with QRS and the presence of T wave flattening.

(4) U WAVES

- Are U waves present or not?

The FOUR INTERVALS (or segments) on an ECG

(1) PR INTERVAL

- The PR interval is normally between 0.12-0.20 seconds (3-5 small squares).
- A prolonged or changing (esp lengthening) PR interval indicates heart block. Shortened PR intervals can be because of WPW or LGL syndromes, or a junctional rhythm.

(2) QRS WIDTH (“QRS-INTERVAL”)

- The QRS-interval is normally less than 0.12 seconds (3 small squares).
- A widened QRS width indicates some sort of conduction defect with the left or right bundle branches.

(3) ST SEGMENT (“ST-INTERVAL”)

- This is probably the most important thing to look at.
- ...then look at it a 2nd and 3rd time. Look for sloping (especially downsloping) or flattening of the ST segments.

(4) QT INTERVAL

- The QT interval is the time from the start of the Q wave to the end of the T wave.

In clinical context

Now we've gone through the system, let's use the "ECG Rule of Fours" to interpret the ECG we were presented with above.

FOUR Initial Features (History, Rate, Rhythm, Axis)

(1) **History**: 60 year old male, weakness and respiratory failure. Lead placement looks ok. (ECG anonymised, but should have a sticker)

- Hmmmm, this is sounding suspicious already...

(2) **Rate** – 90 per minute.

(3) **Rhythm** – Sinus rhythm (P-waves followed by QRS complexes).

(4) **Axis** – about 60 degrees (using Super Axis Man in leads I and aVF).

FOUR Waves (P, QRS, T, U)

(1) **P-waves** – present but peaked (p-pulmonale).

(2) **QRS “waves”** – all looking pretty normal.

(3) **T-waves** – very unusual looking, generally widespread biphasic pattern. Difficult to distinguish from U-waves... Actually, they ARE U-waves! There is also T/U wave discordance in V2.

(4) **U-waves** – Enough said!

FOUR Intervals (PR, QRS, ST, QT)

(1) **PR interval** – looks a bit long. Computer says 212ms... I'll go with the computer...

(2) **QRS complex “interval”** – looks quite narrow, definitely not widened.

(3) **ST segment “interval”** – difficult to tell. In most leads, it almost looks like there is down-sloping ST depression, but I think in the context of what we already know (especially the history), I think an ischaemic cause is not the top diagnosis.

(4) **QT interval** – looks long, and in fact some would say the QT should really be measured at the end of the U wave! Computer says 504ms... so let's lock it in!

What is the diagnosis?

These ECG changes are typical of hypokalaemia.

But even if you didn't know that, using the "ECG Rule of Fours" you would still be able to accurately *describe* the ECG to a more experienced practitioner (e.g. your boss, over the phone), leading to the diagnosis.

7 step approach to ECG rhythm analysis

1. RATE

- Tachycardia or bradycardia?
- Normal rate is 60-100/min.

2. PATTERN OF QRS COMPLEXES

- Regular or irregular?
- If irregular is it regularly irregular or irregularly irregular?

3. QRS MORPHOLOGY

- **Narrow complex:** sinus, atrial or junctional origin.
- **Wide complex:** ventricular origin, or supraventricular with aberrant conduction.

4. P WAVES

- **Absent:** sinus arrest, atrial fibrillation
- **Present:** morphology and PR interval may suggest sinus, atrial, junctional or even retrograde from the ventricles.

5. RELATIONSHIP BETWEEN P WAVES AND QRS COMPLEXES

- **AV association** (may be difficult to distinguish from isorhythmic dissociation)
- **AV dissociation**
 - *complete:* atrial and ventricular activity is always independent.
 - *incomplete:* intermittent capture.

6. ONSET AND TERMINATION

- **Abrupt:** suggests re-entrant process.
- **Gradual:** suggests increased automaticity.

7. RESPONSE TO VAGAL MANOEUVRES

- **Sinus tachycardia, ectopic atrial tachydysrhythmia:** gradual slowing during the vagal manoeuvre, but resumes on cessation.
- **AVNRT or AVRT:** abrupt termination or no response.
- **Atrial fibrillation and atrial flutter:** gradual slowing during the manoeuvre.
- **VT:** no response.

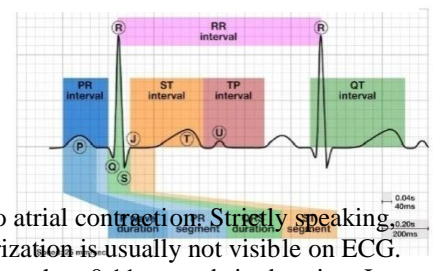
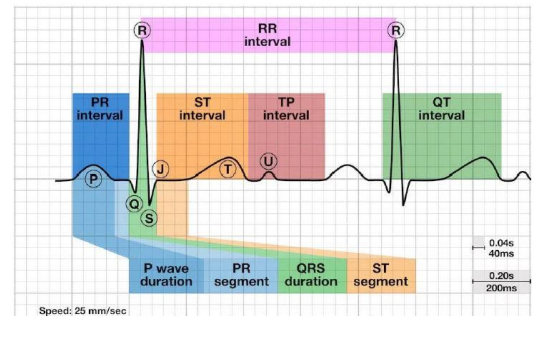
P Wave

P Wave

The P wave represents the depolarization of the left and right atrium and also corresponds to atrial contraction. Strictly speaking the atria contract a split second after the P wave begins. Because it is so small, atrial repolarization is usually not visible on ECG. In most cases, the P wave will be smooth and rounded, no more than 2.5 mm tall, and no more than 0.11 seconds in duration. It will be positive in leads I, II, aVF and V1 through V6.

ABSENT P WAVE

The P waves are not discernible in the following conditions:



- *Atrial fibrillation* In atrial fibrillation, P waves are replaced by numerous, small, irregularly occurring fibrillatory waves, producing a ragged base-line.
- *Atrial flutter* In atrial flutter, P waves are replaced by flutter waves (F waves) that give the baseline a corrugated or saw-toothed appearance.
- *Junctional rhythm* In a junctional rhythm, P waves may just precede, just follow or are buried in the QRS complexes due to near simultaneous activation of the ventricles anterogradely and the atria retrogradely.
- *Ventricular tachycardia* In ventricular tachycardia, P waves are difficult to identify as they lie buried in the wide QRS complexes.
- *Hyperkalemia* In hyperkalemia, P waves are reduced in amplitude or altogether absent. This is associated with tall T waves and wide QRS complexes.

INVERTED P WAVE

The P waves are normally upright in leads L_{II}, L_{III} and aVF, since the atria are activated above downwards towards the inferior leads. If activation of the atria occurs retrogradely from below upwards, the P waves in these leads are negative or inverted. Inverted P waves are thus observed in the following conditions:

- *Junctional rhythm* In a junctional rhythm, inverted P waves may just precede or just follow the QRS complexes.
- *By-pass tract* Inverted P waves are seen if the atria are activated retrogradely through an accessory pathway bypassing the A-V node. This is known as a by-pass tract and occurs in WPW syndrome.

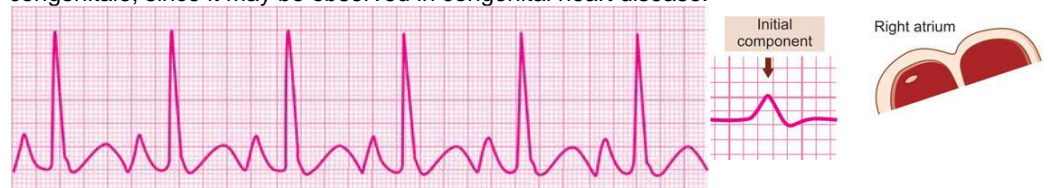CHANGING P WAVE MORPHOLOGY

- *Wandering pacemaker rhythm* In this rhythm the pacemaker, so to say, wanders from one focus to the other. The focus of origin of impulses varies from SA node to atrium to AV junction. This results in P waves of variable morphology.
- *Multifocal atrial tachycardia* In this rhythm, impulses arise from multiple atrial foci to produce an atrial tachycardia or a chaotic pattern of atrial activation. Therefore, the P wave configuration changes from beat to beat.

TALL P WAVE

The normal P wave is less than 2.5 mm in height. It is the sum of right and left atrial activation, right preceding the left. If the right atrium is enlarged, the deflection of the right atrium is superimposed on the left atrial deflection resulting in a tall P wave exceeding 2.5 mm in height.

Therefore, a tall P wave is representative of right atrial enlargement. Of the biphasic P wave in lead V₁, the initial component is larger. A tall P wave is also known as P pulmonale, since it is often caused by pulmonary hypertension or P congenitale, since it may be observed in congenital heart disease.

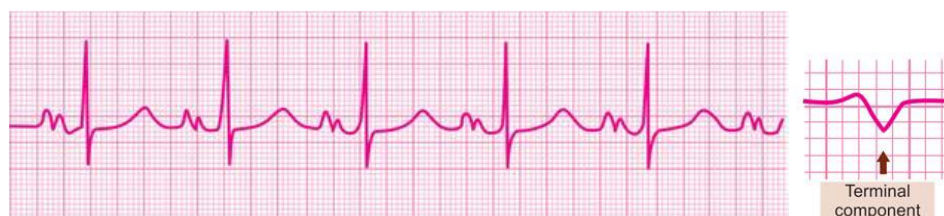

pulmonale: Tall and peaked P wave

P wave in V₁; large initial component

BROAD P WAVE

Therefore, a broad and notched P wave is representative of left atrial enlargement. Of the biphasic P wave in lead V₁, the terminal component is larger. A broad and notched P wave is also known as P. mitrale since it is often associated with mitral valve disease. The common causes of atrial enlargement have been enumerated



P wave abnormalities in right and left atrial enlargement

PR Interval

The **PR interval** is the time from the onset of the P wave to the start of the QRS complex. It reflects conduction through the AV node.

- The normal PR interval is between 120 – 200 ms (0.12-0.20s) in duration (three to five small squares).
- If the PR interval is > 200 ms, first degree heart block is said to be present.
- PR interval < 120 ms suggests pre-excitation (the presence of an accessory pathway between the atria and ventricles) or **AV nodal (junctional) rhythm**.

Prolonged PR Interval – AV block (PR >200ms)

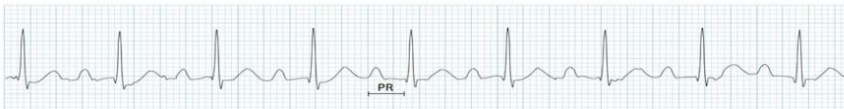
- Delayed conduction through the AV node
- May occur in isolation or co-exist with other blocks (e.g., second-degree AV block, trifascicular block)

FIRST DEGREE HEART BLOCK

DEFINITION

PR interval > 200ms (five small squares)

- There is delay, without interruption, in conduction from atria to ventricles
- 'Marked' first degree heart block is present if PR interval > 300ms



First degree heart block

CAUSES OF FIRST DEGREE HEART BLOCK

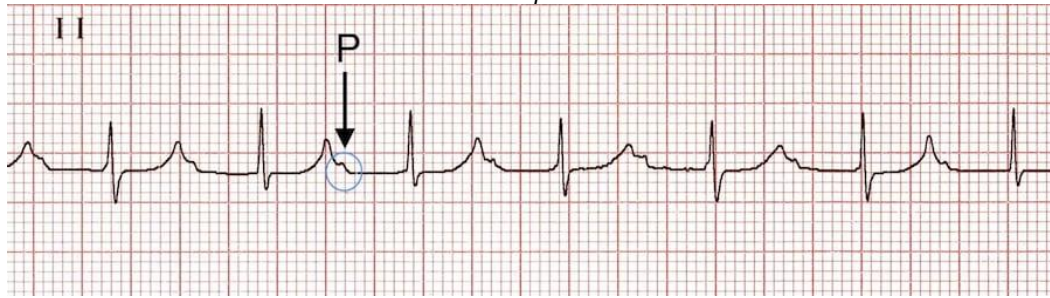
- Increased vagal tone
- Athletic training
- Inferior MI
- Mitral valve surgery
- Myocarditis (e.g. Lyme disease)
- Electrolyte disturbances (e.g. Hyperkalaemia)
- AV nodal blocking drugs (beta-blockers, calcium channel blockers, digoxin, amiodarone)
- May be a normal variant

CLINICAL SIGNIFICANCE

- As an isolated finding this is a benign entity that does not cause haemodynamic instability
- No specific treatment is required

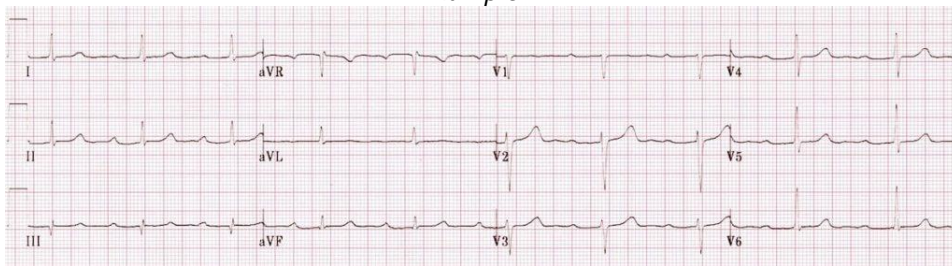
ECG EXAMPLES

Example 1



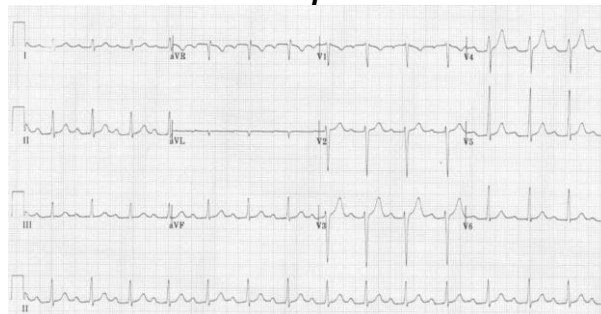
- Marked first degree heart block
- PR interval > 300 ms, P waves are buried in the preceding T wave

Example 2



- Sinus bradycardia with 1st degree AV block
- PR interval > 300 ms

Example 3



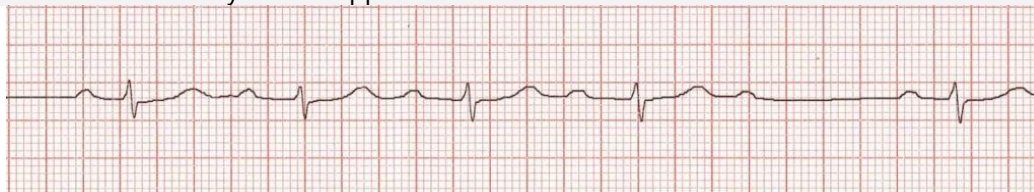
- Normal sinus rhythm with 1st degree AV block
- PR interval 260 ms

SECOND DEGREE AV BLOCK (MOBITZ I) WITH PROLONGED PR INTERVAL

DEFINITION OF MOBITZ I BLOCK (WENCKEBACH PHENOMENON)

Progressive prolongation of the PR interval culminating in a non-conducted P wave:

- PR interval is longest immediately before dropped beat
- PR interval is shortest immediately after dropped beat



AV block: 2nd degree, Mobitz type I

OTHER FEATURES:

- The P-P interval remains relatively constant
- The *greatest increase* in PR interval duration is typically *between the first and second beats of the cycle*
- The RR interval progressively shortens with each beat of the cycle
- The Wenckebach pattern tends to repeat in P:QRS groups with ratios of 3:2, 4:3 or 5:4

MECHANISM

- Mobitz I is usually due to reversible conduction block at the level of the AV node
- Malfunctioning AV nodal cells tend to progressively fatigue until they fail to conduct an impulse. This is different to cells of the His-Purkinje system which tend to fail suddenly and unexpectedly (i.e. producing a Mobitz II block)

CAUSES OF WENCKEBACH PHENOMENON

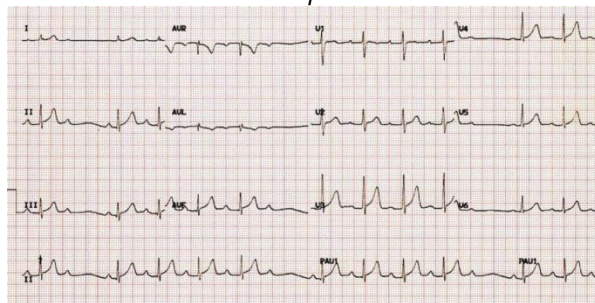
- Drugs: beta-blockers, calcium channel blockers, digoxin, amiodarone
- Increased vagal tone (e.g. athletes)
- Inferior MI
- Myocarditis
- Following cardiac surgery (mitral valve repair, Tetralogy of Fallot repair)

CLINICAL SIGNIFICANCE

- Mobitz I is usually a benign rhythm, causing minimal haemodynamic disturbance and with low risk of progression to third degree heart block
- Asymptomatic patients do not require treatment
- Symptomatic patients usually respond to atropine
- Permanent pacing is rarely required

ECG EXAMPLES

Example 1

**Mobitz I AV block**

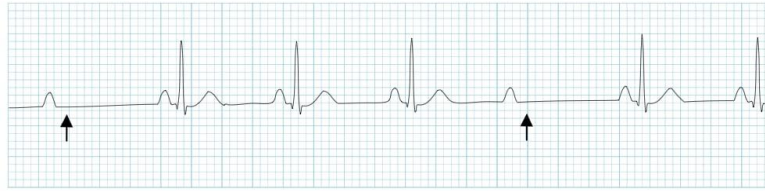
- Progressive prolongation of PR interval, with a subsequent non-conducted P wave
- Repeating 5:4 conduction ratio of P waves to QRS complexes
- Relatively constant P-P interval despite irregularity of QRS complexes

The first clue to the presence of Mobitz I AV block on this ECG is the way the QRS complexes cluster into groups, separated by short pauses. This phenomenon usually represents 2nd-degree AV block or non-conducted PACs; occasionally SA exit block.

MOBITZ II BLOCK (HAY BLOCK)

DEFINITION OF MOBITZ II BLOCK (HAY BLOCK)

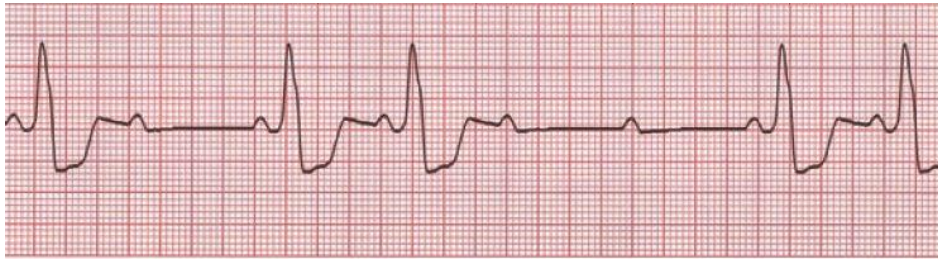
A form of 2nd degree AV block in which there is intermittent non-conducted P waves **without** progressive prolongation of the PR interval



Arrows indicate "dropped" QRS complexes (i.e. non-conducted P waves)

OTHER FEATURES:

- The PR interval in the conducted beats remains constant
- The P waves 'march through' at a constant rate
- The RR interval surrounding the dropped beat(s) is an exact multiple of the preceding RR interval (e.g. double the preceding RR interval for a single dropped beat, triple for two dropped beats, etc)



Mobitz type II rhythm strip demonstrating non-conducted P waves

MECHANISM

- Mobitz II is usually due to failure of conduction at the level of the His-Purkinje system (i.e. below the AV node)
- While Mobitz I is usually due to a functional suppression of AV conduction (e.g. due to drugs, reversible ischaemia), Mobitz II is more likely to be due to *structural* damage to the conducting system (e.g. infarction, fibrosis, necrosis)
- Patients typically have a pre-existing LBBB or bifascicular block, and the 2nd degree AV block is produced by intermittent failure of the remaining fascicle ("bilateral bundle-branch block")
- In around 75% of cases, the conduction block is located *distal to the Bundle of His*, producing *broad QRS complexes*.
- In the remaining 25% of cases, the conduction block is located within the His Bundle itself, producing narrow QRS complexes.
- Unlike Mobitz I, which is produced by progressive fatigue of the AV nodal cells, Mobitz II is an "all or nothing" phenomenon whereby the His-Purkinje cells suddenly and unexpectedly fail to conduct a supraventricular impulse.
- There may be no pattern to the conduction blockade, or alternatively there may be a fixed relationship between the P waves and QRS complexes, e.g. 2:1 block, 3:1 block.

CAUSES OF MOBITZ II

- Anterior MI (due to septal infarction with necrosis of the bundle branches)
- Idiopathic fibrosis of the conducting system (Lenègre-Lev disease)
- Cardiac surgery, especially surgery occurring close to the septum e.g. mitral valve repair
- Inflammatory conditions (rheumatic fever, myocarditis, Lyme disease)
- Autoimmune (SLE, systemic sclerosis)
- Infiltrative myocardial disease (amyloidosis, haemochromatosis, sarcoidosis)
- Hyperkalaemia
- Drugs: beta-blockers, calcium channel blockers, digoxin, amiodarone

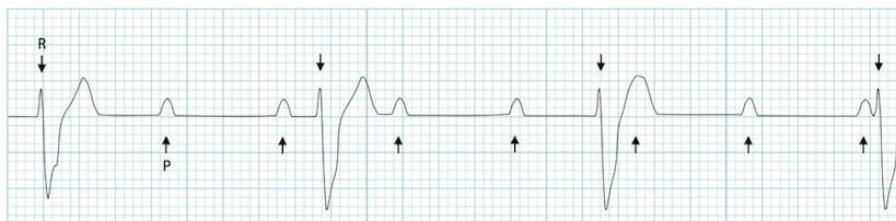
CLINICAL SIGNIFICANCE

- Mobitz II is much more likely than Mobitz I to be associated with haemodynamic compromise, severe bradycardia and progression to 3rd degree heart block
- Onset of haemodynamic instability may be sudden and unexpected, causing syncope (Stokes-Adams attacks) or sudden cardiac death
- The risk of asystole is around 35% per year
- Mobitz II mandates immediate admission for cardiac monitoring, backup temporary pacing and ultimately insertion of a permanent pacemaker

3rd degree or complete heart block

ECG FEATURES OF COMPLETE HEART BLOCK

- Severe bradycardia due to absence of AV conduction
- The ECG demonstrates complete **AV dissociation**, with independent atrial and ventricular rates



Complete heart block: There is AV dissociation, with the atrial rate (~100 bpm) independent of the ventricular rate (~40 bpm)

In complete heart block, there is complete absence of AV conduction, with *none* of the supraventricular impulses conducted to the ventricles. The perfusing rhythm is maintained by junctional or ventricular escape rhythm. Alternatively, the patient may suffer ventricular standstill leading to syncope (if self-terminating) or sudden cardiac death (if prolonged).

PATHOPHYSIOLOGY

- Complete heart block is essentially the end point of either Mobitz I or Mobitz II AV block
- It may be due to progressive fatigue of AV nodal cells as per Mobitz I (e.g. secondary to increased vagal tone in the acute phase of an inferior MI)
- Alternatively, it may be due to sudden onset of complete conduction failure throughout the His-Purkinje system, as per Mobitz II. This can be secondary to septal infarction in acute anterior MI, or as a result of progression of conducting system disease causing true trifascicular block
- The former is more likely to respond to atropine and has a better overall prognosis

CAUSES OF COMPLETE HEART BLOCK

The causes are the same as for Mobitz I and Mobitz II second degree heart block. The most important aetiologies are:

- Inferior myocardial infarction
- AV-nodal blocking drugs (e.g. calcium-channel blockers, beta-blockers, digoxin)
- Idiopathic degeneration of the conducting system (Lenegre's or Lev's disease), causing true trifascicular block

Clinical significance

- Patients with third degree heart block are at high risk of ventricular standstill and sudden cardiac death
- They require urgent admission for cardiac monitoring, backup temporary pacing and usually insertion of a permanent pacemaker

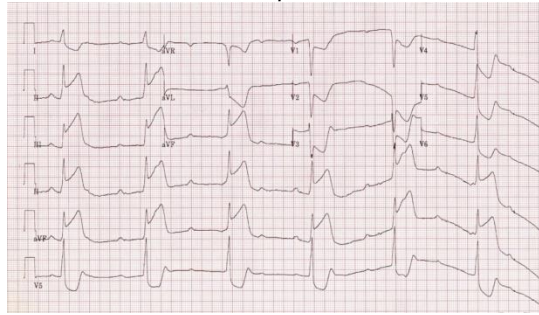
DIFFERENTIAL DIAGNOSIS

Complete heart block should not be confused with:

- **High grade AV block:** A type of severe second degree heart block with a very slow ventricular rate but still some evidence of occasional AV conduction
- **AV dissociation:** This term indicates only the occurrence of *independent atrial and ventricular contractions* and may be caused by entities other than complete heart block (e.g. "interference-dissociation" due to the presence of a ventricular rhythm such as AIVR or VT)

ECG EXAMPLES

Example 1

**Complete Heart Block:**

- Atrial rate is ~ 85 bpm
- Ventricular rate is ~ 38 bpm
- None of the atrial impulses appear to be conducted to the ventricles
- Rhythm is maintained by a junctional escape rhythm
- Marked inferior ST elevation indicates that the cause is an inferior STEMI

Short PR interval (< 120ms)

A short PR interval is seen with:

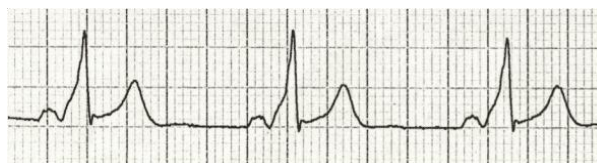- Preexcitation syndromes
- AV nodal (junctional) rhythm.

Pre-excitation syndromes

- **Wolff-Parkinson-White (WPW)** and **Lown-Ganong-Levine (LGL)** syndromes.
- These involve the presence of an accessory pathway connecting the atria and ventricles.
- The accessory pathway conducts impulses faster than normal, producing a short PR interval.
- The accessory pathway also acts as an anatomical re-entry circuit, making patients susceptible to re-entry tachyarrhythmias.
- Patients present with episodes of paroxysmal supraventricular tachycardia (SVT), specifically atrioventricular re-entry tachycardia (AVRT), and characteristic features on the resting 12-lead ECG.

WOLFF-PARKINSON-WHITE SYNDROME

The characteristic features of Wolff-Parkinson-White syndrome are a short PR interval (<120ms), broad QRS and a slurred upstroke to the QRS complex, the delta wave.

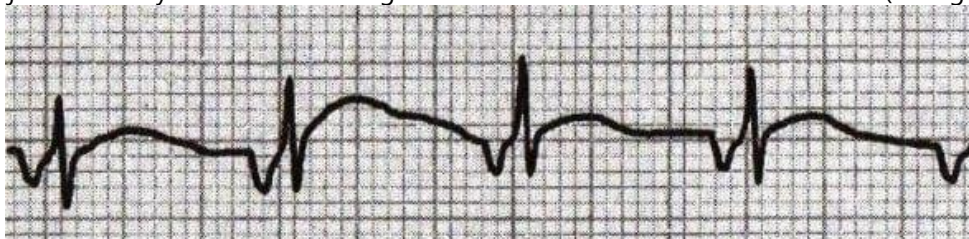


LOWN-GANONG-LEVINE SYNDROME

The features of Lown-Ganong-Levine syndrome LGL syndrome are a very short PR interval with normal P waves and QRS complexes and absent delta waves.

AV NODAL (JUNCTIONAL) RHYTHM

- Junctional rhythms are narrow complex, regular rhythms arising from the AV node.
- P waves are either absent or abnormal (e.g. inverted) with a short PR interval (=retrograde P waves).
- ECG: Accelerated junctional rhythm demonstrating inverted P waves with a short PR interval (retrograde P waves)



PR segment abnormalities

These occur in two main conditions:

- Pericarditis
- Atrial ischaemia

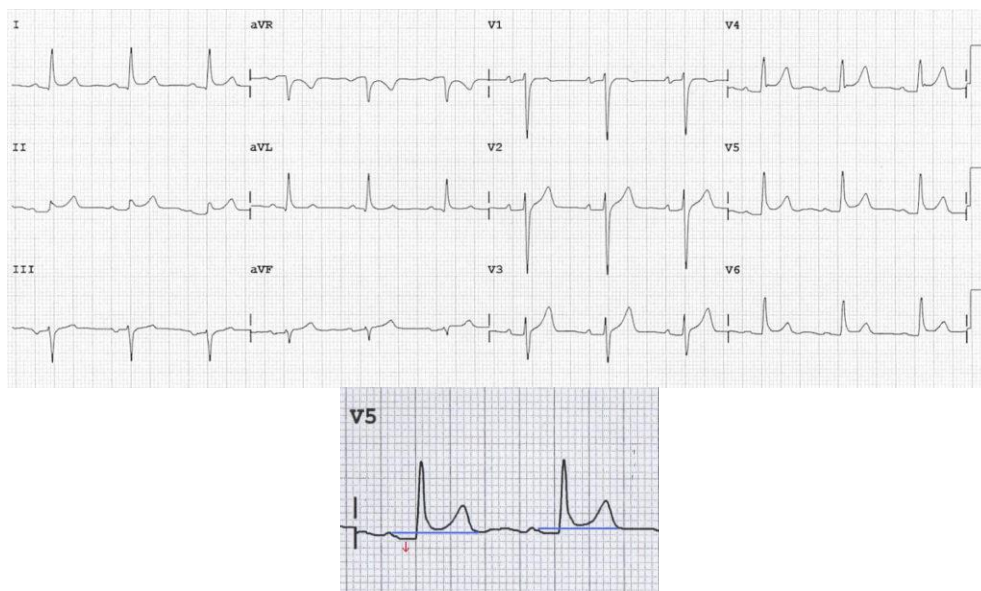Pericarditis

The characteristic changes of acute pericarditis are:

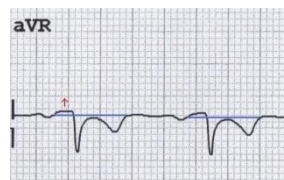- PR segment depression.
- Widespread concave ('saddle-shaped') ST elevation.
- Reciprocal ST depression and PR elevation in aVR and V1
- Absence of reciprocal ST depression elsewhere.

NB. PR segment changes are relative to the baseline formed by the T-P segment.

Typical ECG of acute pericarditis.



PR segment depression in V5 due to acute pericarditis (note also some concave ST elevation)



PR elevation in aVR due to acute pericarditis (note the reciprocal ST depression)

Atrial ischaemia

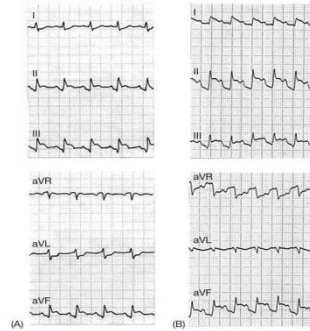
- PR segment elevation or depression in patients with myocardial infarction indicates concomitant atrial ischaemia or infarction.
- This finding has been associated with poor outcomes following MI, increased risk for the development of atrioventricular block, supraventricular arrhythmias and cardiac free-wall rupture.

Liu's criteria for diagnosing atrial ischaemia / infarction include:

- PR elevation >0.5 mm in V₅ & V₆ with reciprocal PR depression in V₁ & V₂
- PR elevation >0.5 mm in lead I with reciprocal PR depression in leads II & III
- PR depression >1.5 mm in the precordial leads
- PR depression >1.2 mm in leads I, II, & III

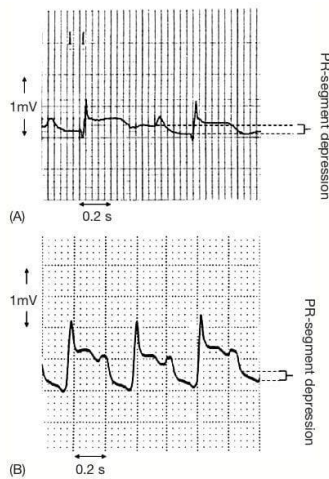
- Abnormal P wave morphology: M-shaped,W-shaped,irregular,or notched (minor criteria)

PR DEPRESSION IN INFERIOR STEMI INDICATING CONCOMITANT ATRIAL INFARCTION



Profound PR-segment depression in inferior leads: (A) with clear-cut TP segment; and (B) without clear-cut TP segment; in acute inferior myocardial infarction. Note also ST-segment elevation in inferior leads. (Reproduced from Jim et al.)

MEASUREMENT OF PR DEPRESSION

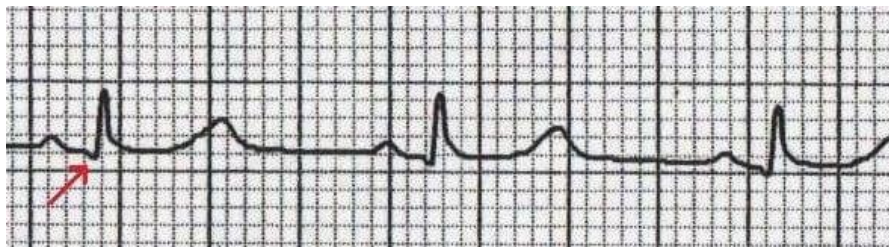


- Measurement of PR-segment depression: (A) with clear-cut TP segment; and (B) without clear-cut TP segment. (Reproduced from Jim et al.)

The Q Wave

A Q wave is any negative deflection that precedes an R wave

- The Q wave represents the normal left-to-right depolarisation of the interventricular septum
- Small 'septal' Q waves are typically seen in the left-sided leads (I, aVL, V5 and V6)
-



Q waves in different leads

- Small Q waves are normal in most leads
- Deeper Q waves (>2 mm) may be seen in leads III and aVR as a normal variant
- Under normal circumstances, Q waves are not seen in the right-sided leads (V1-3)

Pathological Q Waves

Q waves are considered pathological if:

- > 40 ms (1 mm) wide

- > 2 mm deep
- > 25% of depth of QRS complex
- Seen in leads V1-3

Pathological Q waves usually indicate current or prior myocardial infarction.

Differential Diagnosis

- Myocardial infarction
- Cardiomyopathies — Hypertrophic (HCM), infiltrative myocardial disease
- Rotation of the heart — Extreme clockwise or counter-clockwise rotation
- Lead placement errors — e.g. upper limb leads placed on lower limbs

Loss of normal Q waves

- The absence of small septal Q waves in leads V5-6 should be considered abnormal.
- Absent Q waves in V5-6 is most commonly due to LBBB.

Pathological Q wave:

1. MI
2. Left ventricular hypertrophy (in V1, V2 and V3)
3. LBBB
4. Pulmonary embolism (only in lead III)
5. WPW syndrome (in lead III and aVF)

R wave Overview

The R wave is the first upward deflection after the P wave. The R wave represents early ventricular depolarisation

Abnormalities of the R wave

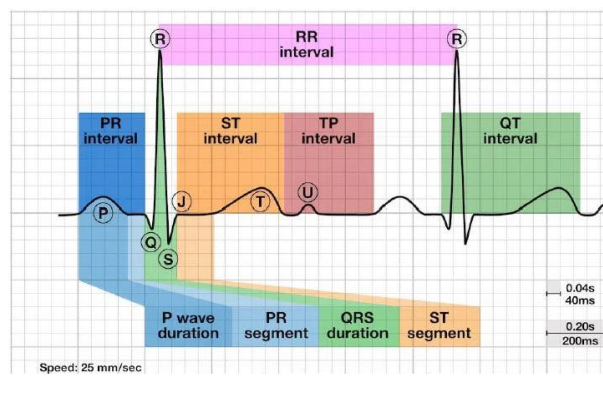
There are three key R wave abnormalities:

1. Dominant R wave in V1
2. Dominant R wave in aVR
3. Poor R wave progression

1. Dominant R wave in V1

- Normal in children and young adults
 - Right Ventricular Hypertrophy (RVH)
 - Pulmonary Embolus
 - Persistence of infantile pattern
 - Left to right shunt
 - Right Bundle Branch Block (RBBB)
 - Posterior Myocardial Infarction (ST elevation in Leads V7, V8, V9)
 - Wolff-Parkinson-White (WPW) Type A
 - Incorrect lead placement (e.g. V1 and V3 reversed)
 - Dextrocardia
 - Hypertrophic cardiomyopathy
 - Dystrophy
 - Myotonic dystrophy
 - Duchenne Muscular dystrophy
- #### *2. Dominant R wave in aVR*
- Poisoning with sodium-channel blocking drugs (e.g. TCAs)
 - Dextrocardia
 - Incorrect lead placement (left/right arm leads reversed)
 - Commonly elevated in ventricular tachycardia (VT)

3. Poor R wave progression

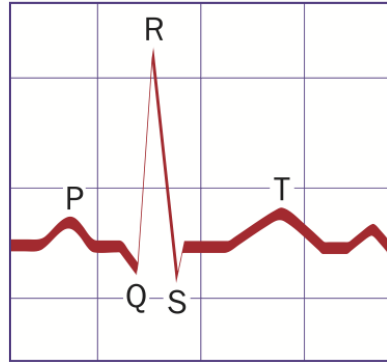


Poor R wave progression is described with an R wave ≤ 3 mm in V3 and is caused by:

- Prior anteroseptal MI
- LVH
- Inaccurate lead placement
- May be a normal variant

S WAVE

The S wave is the first downward deflection of the QRS complex that occurs after the R wave. However, a S wave may not be present in all ECG leads in a given patient.



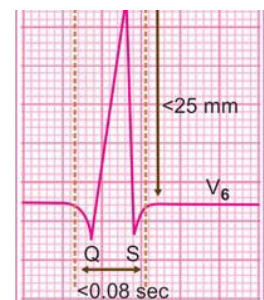
In the normal ECG, there is a large S wave in V1 that progressively becomes smaller, to the point that almost no S wave is present in V6. A large slurred S wave is seen in leads I and V6 in the setting of a right bundle branch block.

The presence or absence of the S wave does not bear major clinical significance. Rarely is the morphology of the S wave discussed.

In the setting of a pulmonary embolism, a large S wave may be present in lead I — part of the S1Q3T3 pattern seen in this disease state. At times, the morphology of the S wave is examined to determine if ventricular tachycardia or supraventricular tachycardia with aberrancy is present; this is discussed elsewhere.

QRS Complex

QRS Complex



As the name suggests, the QRS complex includes the Q wave, R wave, and S wave. These three waves occur in rapid succession. The QRS complex represents the electrical impulse as it spreads through the ventricles and indicates ventricular depolarization. As with the P wave, the QRS complex starts just before ventricular contraction.

It is important to recognize that not every QRS complex will contain Q, R, and S waves. The convention is that the Q wave is always negative and that the R wave is the first positive wave of the complex. If the QRS complex only includes an upward (positive) deflection, then it is an R wave. The S wave is the first negative deflection after an R wave.

Under normal circumstances, the duration of the QRS complex in an adult patient will be between 0.06 and 0.10 seconds. The QRS complex is usually positive in leads I, aVL, V5, V6 and II, III, and aVF. The QRS complex is usually negative in leads aVR, V1, and V2.

The J-point is the point where the QRS complex and the ST segment meet. It can also be thought of as the start of the ST segment. The J-point (also known as Junction) is important because it can be used to diagnose an ST segment elevation myocardial infarction. When the J-point is elevated at least 2 mm above baseline, it is consistent with a STEMI.

- R wave voltage is at least 5 mm in the limb leads and at least 10 mm in the precordial leads.
- There is normally no variation in the QRS voltage of consecutive beats in a particular lead.
 - The normal QRS axis ranges from -30° to $+90^{\circ}$ on the hexaxial reference system.
- R wave magnitude increases gradually from lead V₁ to lead V₆ representing transition from right ventricular to left ventricular QRS complexes.
- Physiological q waves are seen in leads L₁, aVL. They are less than 25 percent of the ensuing R wave in size and less than 0.04 second in duration.
 - R wave voltage does not exceed 4 mm in lead V₁ and is not more than 25 mm in lead V₅ and V₆.
- The normal S wave is larger than the r wave in lead V₁ and smaller than the R wave in lead V₆. It does not exceed a depth of 7 mm in lead V₆.

The width of the normal QRS complex does not exceed 0.08 sec or 2 small squares.

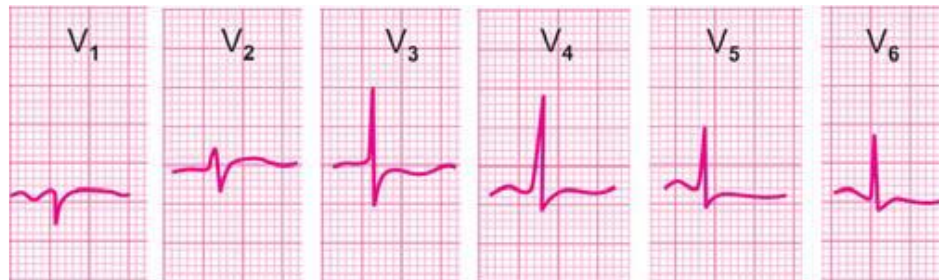
Abnormalities of QRS Complex

LOW-VOLTAGE QRS COMPLEX

The voltage of the R wave in the QRS complex is normally at least 5 mm in the limb leads and at least 10 mm in the precordial leads. If the voltage of the tallest R wave in the limb leads is less than 5 mm and that in the precordial leads is less than 10 mm, the electrocardiogram obtained is called a low voltage graph.













Accordingly, the causes of a low voltage ECG graph can be classified as follows:

- *Due to low voltage generation*
 - Hypothyroidism
 - Constrictive pericarditis
 - Diffuse myocardial disease



Hypothyroidism: Low voltage graph; T wave inversion

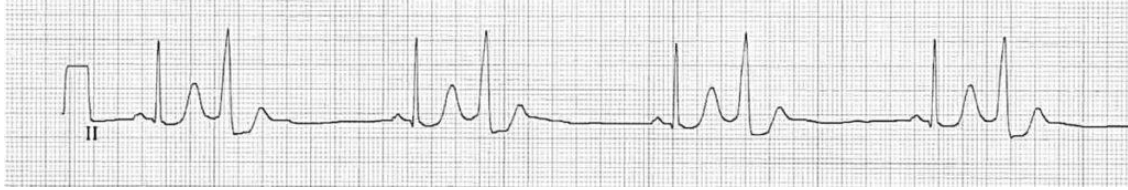QRS COMPLEX NAMING CONVENTION

 <p>R</p> <p>The first (and only) wave is positive and thus an R wave.</p>	 <p>RS</p> <p>The first wave is large and positive (R), followed by a small negative wave (s).</p>	 <p>rS</p> <p>Initially a small positive wave (r), followed by a large negative wave (S).</p>	 <p>qRS</p> <p>The first wave is negative and small (q), followed by a large positive wave (R), and finally a small negative wave (s).</p>
 <p>QR</p> <p>Initially a large negative (Q), then a large positive wave (R).</p>	 <p>QS</p> <p>A single negative wave is called a QS-complex.</p>	 <p>Qr</p> <p>A large negative wave (Q), followed by a small positive wave (r).</p>	 <p>rsR'</p> <p>The negative wave manages to pass the baseline, and is therefore qualified as an S wave.</p>
 <p>qR</p> <p>Initially a small negative wave (q), followed by a large positive wave (R).</p>	 <p>R</p> <p>Notching on the upstroke of the R wave.</p>	 <p>rR'</p> <p>The negative deflection does not manage to pass the baseline and can therefore qualify as an s wave.</p>	 <p>Examples of fragmented QRS-complexes.</p>

QRS Width

Normal QRS width is 70-100 ms (a duration of 110 ms is sometimes observed in healthy subjects). The QRS width is useful in determining the origin of each QRS complex (e.g. sinus, atrial, junctional or ventricular).

- **Narrow complexes** (QRS < 100 ms) are **supraventricular** in origin.
- **Broad complexes** (QRS > 100 ms) may be either **ventricular** in origin, or due to **aberrant conduction** of supraventricular complexes (e.g. due to bundle branch block, hyperkalaemia or sodium-channel blockade).



Example ECG showing both narrow and broad complexes

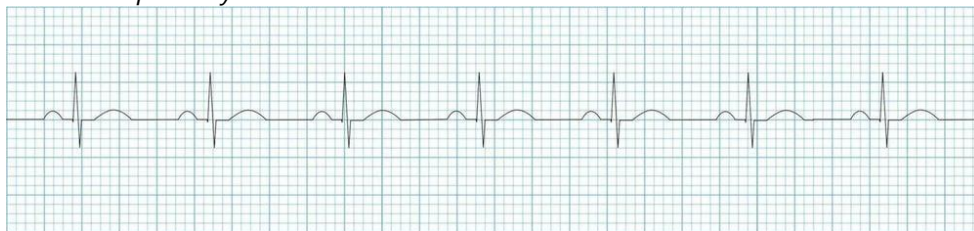Sinus rhythm with frequent ventricular ectopic beats (VEBs) in a pattern of ventricular bigeminy. The narrow beats are sinus in origin, the broad complexes are ventricular.

Narrow QRS Complex Morphology

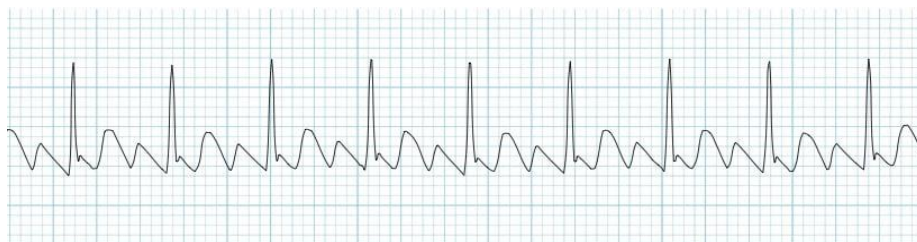
Narrow (supraventricular) complexes arise from three main places:

- Sino-atrial node (= normal P wave)
- Atria (= abnormal P wave / flutter wave / fibrillatory wave)
- AV node / junction (= either no P wave or an abnormal P wave with a PR interval < 120 ms)

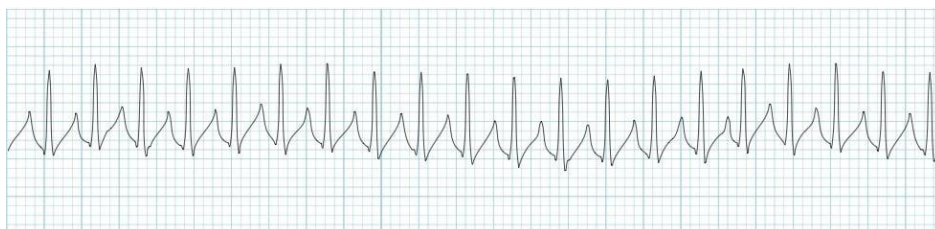
Examples of Narrow Complex Rhythms:



Sinus rhythm: Each narrow complex is preceded by a normal P wave.



Atrial flutter: Narrow QRS complexes are associated with regular flutter waves.



Junctional tachycardia: Narrow QRS complexes with no visible P waves.

Broad QRS Complex Morphology

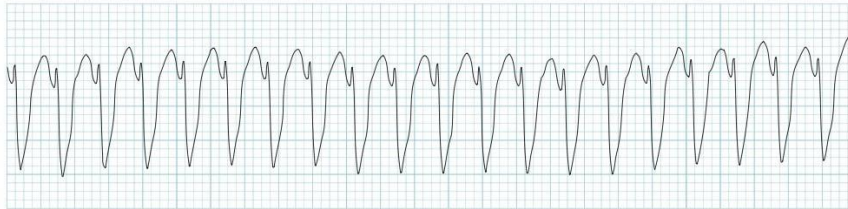
Broad/Wide QRS Complexes

- A QRS duration > 100 ms is abnormal
- A QRS duration > 120 ms is required for the diagnosis of bundle branch block or ventricular rhythm

Broad complexes may be ventricular in origin or due to aberrant conduction secondary to:

- Bundle branch block (RBBB or LBBB)
- Hyperkalaemia
- Poisoning with sodium-channel blocking agents (e.g. tricyclic antidepressants)
- Pre-excitation (i.e. Wolff-Parkinson-White syndrome)
- Ventricular pacing
- Hypothermia
- Intermittent aberrancy (e.g. rate-related aberrancy)

Example of a Broad Complex Rhythm:



Ventricular tachycardia: Broad QRS complexes with no visible P waves

Ventricular vs supraventricular rhythms

Differentiation between **ventricular** complexes and **aberrantly conducted** supraventricular complexes may be difficult.

- In general, aberrant conduction of sinus rhythm and atrial rhythms (tachycardia, flutter, fibrillation) can usually be identified by the presence of preceding atrial activity (P waves, flutter waves, fibrillatory waves).
- However, aberrantly conducted junctional (AV nodal) complexes may appear identical to ventricular complexes as both produce broad QRS *without* any preceding atrial activity.
- In the case of ectopic beats, this distinction is not really important (as occasional ectopic beats do not usually require treatment).
- However, in the case of sustained tachyarrhythmias, the distinction between ventricular tachycardia and SVT with aberrancy becomes more important. This topic is covered in more detail here.

Fortunately, many causes of broad QRS can be identified by pattern recognition:

- Right bundle branch block produces an RSR' pattern in V1 and deep slurred S waves in the lateral leads.
- Left bundle branch block produces a dominant S wave in V1 with broad, notched R waves and absent Q waves in the lateral leads.
- Hyperkalaemia is associated with a range of abnormalities including peaked T waves
- Tricyclic poisoning is associated with sinus tachycardia and tall R' wave in aVR
- Wolff-Parkinson White syndrome is characterised by a short PR interval and delta waves
- Ventricular pacing will usually have visible pacing spikes
- Hypothermia is associated with bradycardia, long QT, Osborn waves and shivering artefact

High Voltage QRS Morphology

- Increased QRS voltage is often taken to infer the presence of left ventricular hypertrophy.
- However, high left ventricular voltage (HLVV) may be a normal finding in patients less than 40-45 years of age, particularly slim or athletic individuals.
- There are multiple "voltage criteria" for left ventricular hypertrophy.
- Probably the most commonly used are the *Sokolov-Lyon criteria* (S wave depth in V1 + tallest R wave height in V5-V6 > 35 mm).
- Voltage criteria must be accompanied by non-voltage criteria to be considered diagnostic of left ventricular hypertrophy.

Low Voltage QRS Morphology

The QRS is said to be low voltage when:

- The amplitudes of all the QRS complexes in the limb leads are < 5 mm; or
- The amplitudes of all the QRS complexes in the precordial leads are < 10 mm

Electrical Alternans

- This is when the QRS complexes alternate in height.
- The most important cause is massive pericardial effusion, in which the alternating QRS voltage is due to the heart swinging back and forth within a large fluid-filled pericardium.

Spot Diagnoses

These cardiac diseases produce **distinctive QRS morphologies** that are important not to miss:

- Brugada syndrome (partial RBBB with ST elevation in V1-2)
- Wolff-Parkinson White Syndrome (delta wave)
- Tricyclic poisoning (wide QRS with dominant R wave in aVR)

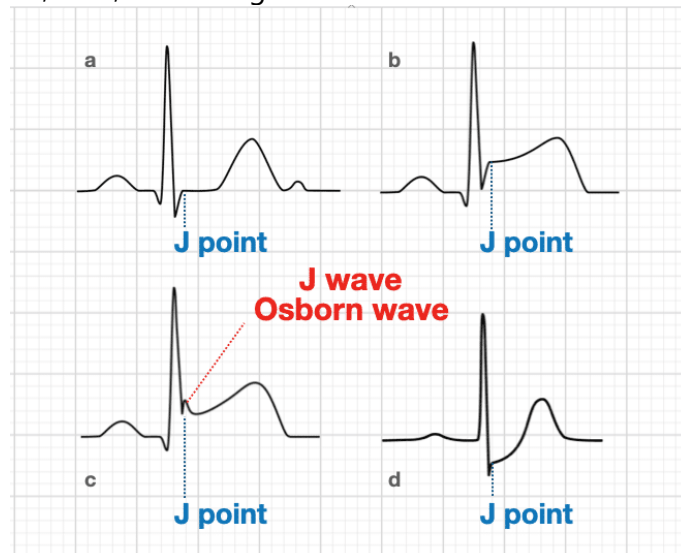
(J WAVE)

OSBORN WAVE (J WAVE) OVERVIEW

The **Osborn wave** (J wave) is a positive deflection seen at the J point in precordial and true limb leads. It is most commonly associated with hypothermia. These changes will appear as a reciprocal, negative deflection in aVR and V1.

The **J point** in the ECG is the point where the QRS complex joins the ST segment. It represents the approximate end of depolarization and the beginning of repolarization as determined by the surface ECG. There is an overlap of around 10ms.

The **J point** may deviate from the baseline in early repolarization, epicardial or endocardial ischemia or injury, pericarditis, RBBB, LBBB, RVH, LVH or digitalis effect.



J point in a) normal; b) J point elevation; c) with Osborn wave (J wave); d) J point depression

Note: The letter J on the ECG defines 2 totally different and unrelated events. The J point is a point in time marking the end of the QRS and the onset of the ST segment present on all ECGs. The J wave is a much less common, slow deflection of uncertain origin originally described in relation to hypothermia.

OSBORN WAVE CAUSES

Characteristically seen in hypothermia (typically $T < 30C$), but they are not pathognomic. Causes of non-hypothermic Osborn waves include:

- Hypercalcaemia [Otero et al]
- Acute myocardial ischaemia [Maruyama et al]
- Takotsubo cardiomyopathy [Zorzi et al]
- Left ventricular hypertrophy due to hypertension [Patel et al]
- Normal variant and early repolarization
- Neurological insults such as intracranial hypertension, severe head injury and subarachnoid haemorrhage
- Severe myocarditis
- Brugada syndrome [Bjerregaard et al]
- Le syndrome d'Haïssaguerre (idiopathic VF)

No definitive physiological cause for the deflection has been described, despite numerous postulates.

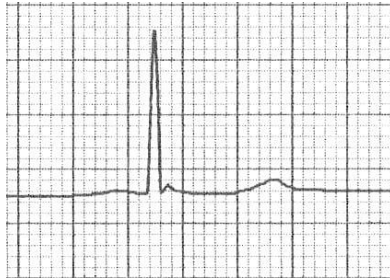
Compared to other hypothermia-induced ECG abnormalities (e.g. sinus bradycardia; supraventricular arrhythmias, QT prolongation and AV block), the Osborn wave is thought to be the most specific.

HISTORY

Eponymously associated with John Jay Osborn (1917-2014) following his 1953 '*current of injury*' description in hypothermic dogs. See below for a deep dive into the eponymous history.

Osborn Wave ECG examples

Example 1



- Subtle J waves in mild hypothermia [Temp: 32.5°C (90.5°F)]
- The height of the J wave is roughly proportional to the degree of hypothermia

CONTROVERSY REGARDING TERMINOLOGY

Occasionally you may encounter other terms used to describe Osborn waves (J waves). Some authors have used the term **J wave deflection** to describe such a large, prominent deviation of the J point from the baseline. Other terms used previously include the "late delta wave", "J-point wave", and the "camel-hump sign of Osborn".

There is little consensus regarding terminology, nature, and prognostic significance of the J wave. In the setting of hypothermia, this phenomenon is most commonly referred to as an Osborn wave.

Abnormalities of the J point

- Elevation or depression of the J point is seen with the various causes of ST segment abnormality. It may be elevated as a result of injury currents during acute myocardial ischemia and pericarditis, as well as in various other patterns of both normal and abnormal ECGs
- Elevation of the J point occurs with benign early repolarisation
- A positive deflection **prior** to the J point is termed a J wave (Osborn wave) and is characteristically seen with hypothermia.

T wave Overview

The T wave is the positive deflection after each QRS complex. It represents ventricular *repolarisation*.

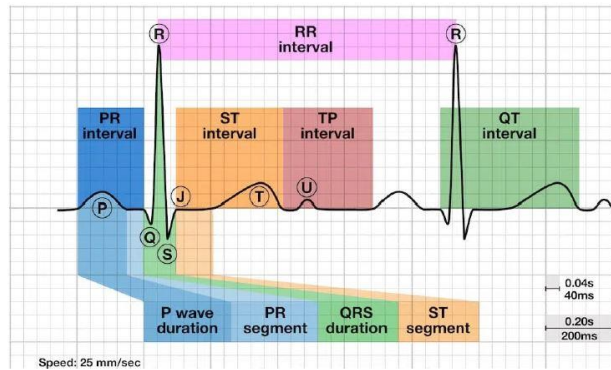
NORMAL T WAVE CHARACTERISTICS

- Upright in all leads except aVR and V1
- Amplitude < 5mm in limb leads, < 10mm in precordial leads (10mm males, 8mm females)

- Duration relates to QT interval

A T wave follows the QRS complex and indicates ventricular repolarization. Unlike a P wave, a normal T wave is slightly asymmetric; the peak of the wave is a little closer to its end than to its beginning. T waves are normally positive in leads I, II, and V2 through V6 and negative in aVR. A T wave will normally follow the same direction as the QRS complex that preceded it (positive or negative/up or down). When a T wave occurs in the opposite direction of the QRS complex, it generally reflects some sort of cardiac pathology.

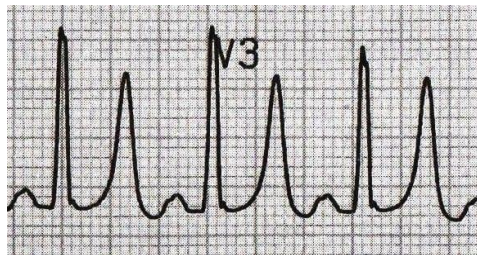
- If a small wave occurs between the T wave and the P wave, it could be a U wave. The biological basis for a U wave is unknown.



T wave abnormalities

- Peaked T waves
- Hyperacute T waves
- Inverted T waves
- Biphasic T waves
- 'Camel Hump' T waves
- Flattened T waves

Peaked T waves

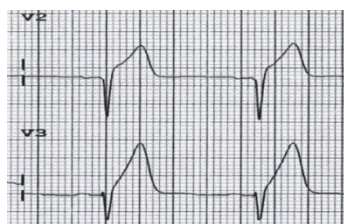


Tall, narrow, symmetrically peaked T-waves are characteristically seen in hyperkalemia

Hyperacute T waves (HATW)

Broad, asymmetrically peaked or 'hyperacute' T-waves (HATW) are seen in the early stages of ST-elevation MI (STEMI), and often precede the appearance of ST elevation and Q waves. Particular attention should be paid to their size in relation to the preceding QRS complex, as HATW may appear 'normal' in size if the preceding QRS complex is of a small amplitude.

They are also seen with Prinzmetal angina.



Prinzmetal angina

LOSS OF PRECORDIAL T-WAVE BALANCE

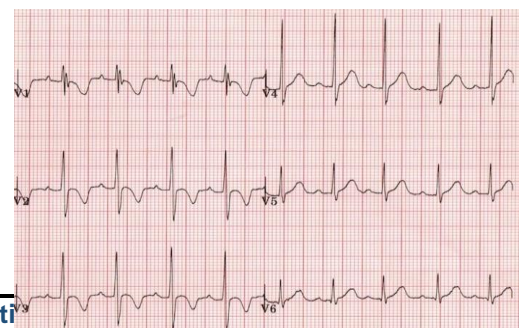
Loss of precordial T-wave balance occurs when the upright T wave is larger than that in V6. This is a type of **hyperacute T wave**.

- The normal T wave in V1 is inverted. An upright T wave in V1 is considered abnormal — especially if it is tall (TTV1), and especially if it is new (NTTV1).
- This finding indicates a high likelihood of coronary artery disease, and when new implies acute ischemia

Inverted T waves

Inverted T waves are seen in the following conditions:

- Normal finding in children



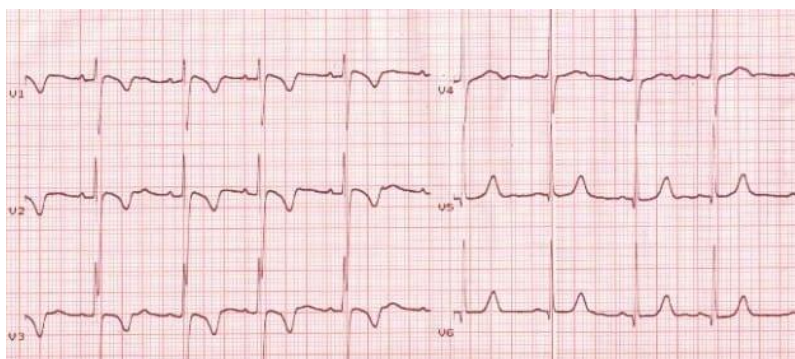
- Persistent juvenile T wave pattern
- Myocardial ischaemia and infarction (including Wellens Syndrome)
- Bundle branch block
- Ventricular hypertrophy ('strain' patterns)
- Pulmonary embolism
- Hypertrophic cardiomyopathy
- Raised intracranial pressure

**** T wave inversion in lead III is a normal variant. New T-wave inversion (compared with prior ECGs) is always abnormal. Pathological T wave inversion is usually symmetrical and deep (>3mm).**

Paediatric T waves

Inverted T-waves in the right precordial leads (V1-3) are a normal finding in children, representing the dominance of right ventricular forces

Persistent Juvenile T-wave Pattern



- T-wave inversions in the right precordial leads may persist into adulthood and are most commonly seen in young Afro-Caribbean women
- Persistent juvenile T-waves are asymmetric, shallow (<3mm) and usually limited to leads V1-3

Myocardial Ischaemia and Infarction

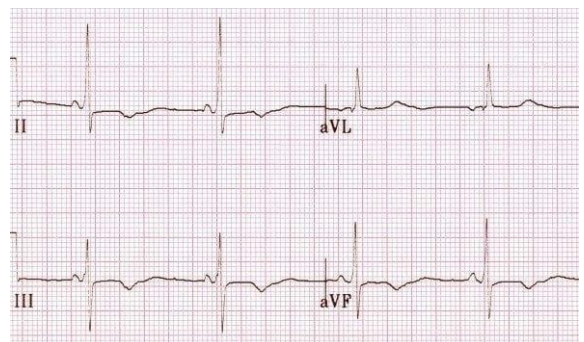
T-wave inversions due to myocardial ischaemia or infarction occur in contiguous leads based on the anatomical location of the area of ischaemia/infarction:

- Inferior = II, III, aVF
- Lateral = I, aVL, V5-6
- Anterior = V2-6

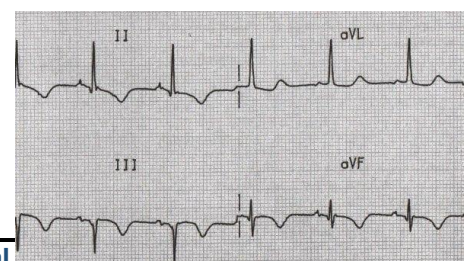
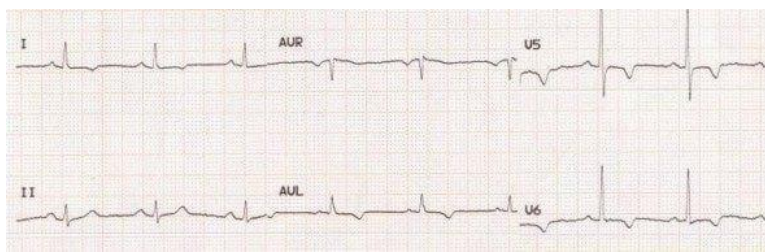
NOTE:

- **Dynamic** T-wave inversions are seen with acute myocardial ischaemia
- **Fixed** T-wave inversions are seen following infarction, usually in association with pathological Q waves

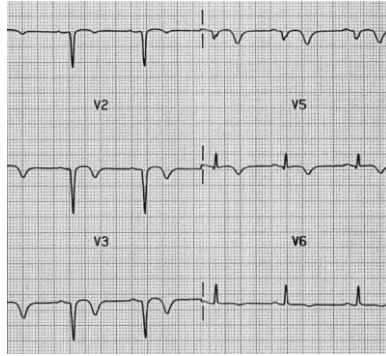
Inferior T wave inversion due to acute ischaemia



Inferior T wave inversion with Q waves – prior myocardial infarction



T wave inversion in the lateral leads due to acute ischaemia



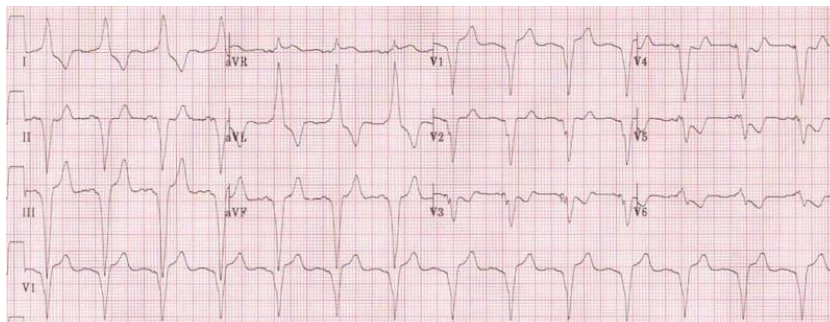
Anterior T wave inversion with Q waves due to recent MI

Bundle Branch Block

In bundle branch block, T-wave inversion is an expected finding, even in the absence of ischaemia:

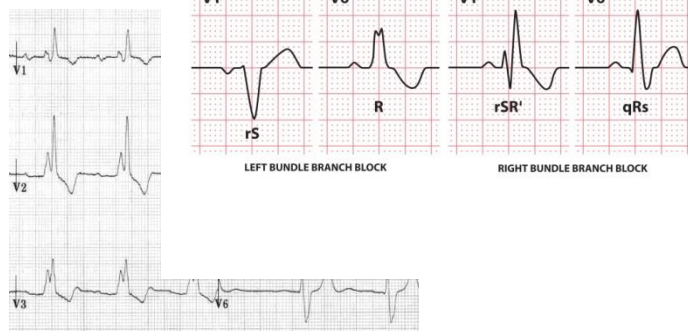
- *Appropriate discordance* refers to the fact that abnormal depolarisation (such as in bundle branch block) should be followed by abnormal repolarisation, which appears discordant to the preceding QRS complex in the form of ST-depression and T-wave inversion

LEFT BUNDLE BRANCH BLOCK



- Left bundle branch block produces T-wave inversion in

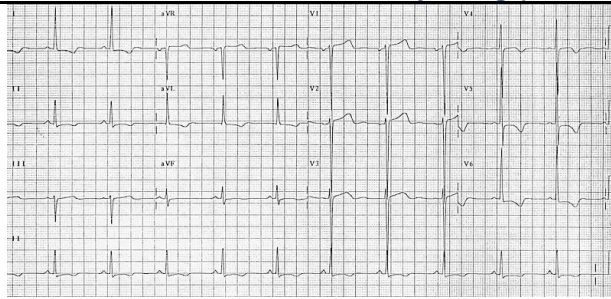
RIGHT BUNDLE



- Right bundle branch block produces T-wave inversion in the right precordial leads V1-3

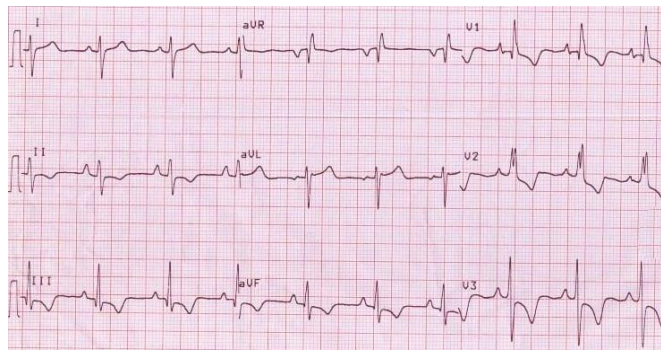
Ventricular Hypertrophy

LEFT VENTRICULAR HYPERTROPHY (LVH)



- Left ventricular hypertrophy (LVH) produces T-wave inversion in the lateral leads I, aVL, V5-6 (left ventricular 'strain' pattern), with a similar morphology to that seen in LBBB

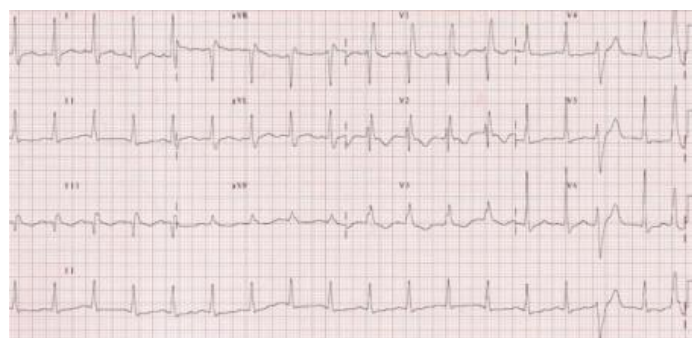
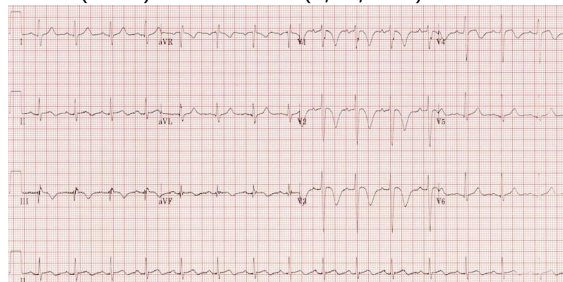
RIGHT VENTRICULAR HYPERTROPHY (RVH)



- Right ventricular hypertrophy produces T-wave inversion in the right precordial leads V1-3 (right ventricular 'strain' pattern) and also the inferior leads (II, III, aVF)

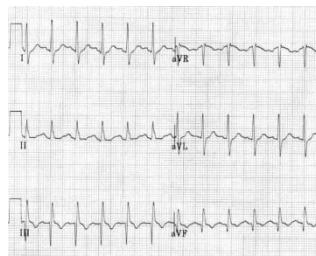
PULMONARY EMBOLISM

- Acute right heart strain (e.g. secondary to massive pulmonary embolism) produces a similar pattern to RVH
- T-wave inversions in the right precordial (V1-3) and inferior (II, III, aVF) leads



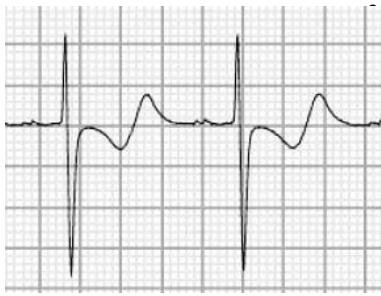
$S_1 Q_{III} T_{III}$

- Pulmonary embolism may also produce T-wave inversion in lead III as part of the $S_1 Q_{III} T_{III}$ pattern
- S wave in lead I, Q wave in lead III, T-wave inversion in lead III



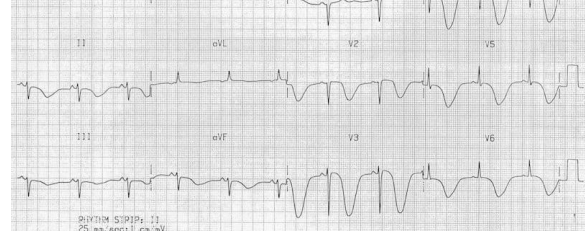
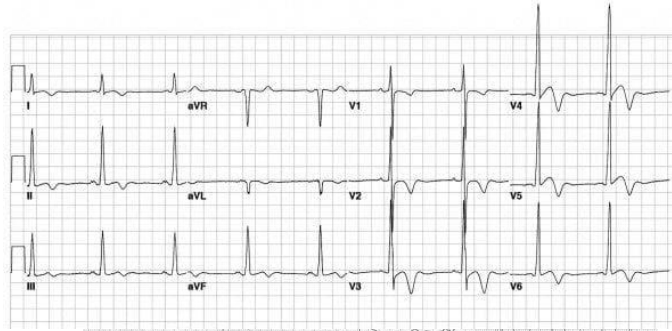
Acute massive PE with **S_IQ_{III}T_{III}** RBBB TWI V1-3

HYPERTROPHIC CARDIOMYOPATHY (HCM)



Hypertrophic

Cardiomyopathy is associated with deep T inversions in all the precordial lead



wave

RAISED INTRACRANIAL PRESSURE (ICP)

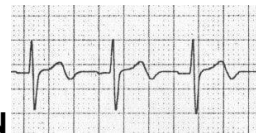- Events causing a sudden rise in intracranial pressure (e.g. subarachnoid haemorrhage) produce widespread deep T-wave inversions with a bizarre morphology

Biphasic T waves

There are two main causes of **biphasic T waves**:

- Myocardial ischaemia
- Hypokalaemia

The two waves go in opposite directions:



Biphasic T waves due to **ischaemia** – T waves go **UP** then **DOWN**

Biphasic T waves due to Hypokalaemia – T waves go **DOWN** then **UP**

Wellens Syndrome

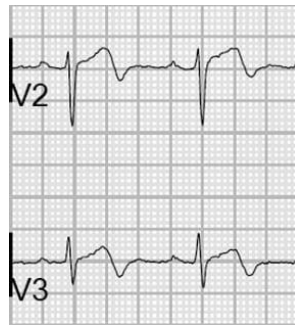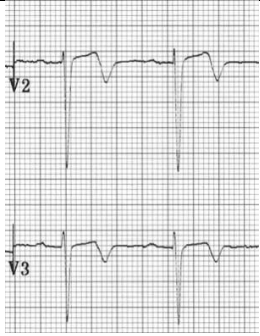
Wellens syndrome is a pattern of inverted or biphasic T waves in V2-3 (in patients presenting with/following ischaemic sounding chest pain) that is highly specific for critical stenosis of the left anterior descending artery.

There are *two patterns* of T-wave abnormality in Wellens syndrome:

- **Type A** = Biphasic T waves with the initial deflection positive and the terminal deflection negative (25% of cases)
- **Type B** = T-waves are deeply and symmetrically inverted (75% of cases)

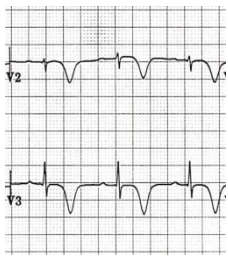
Note: The T waves evolve over time from a Type A to a Type B pattern

WELLENS TYPE A

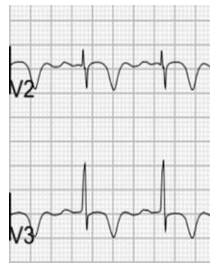

Wellens Pattern A (Type 1)

Wellens Pattern A (Type 1)



WELLENS TYPE B



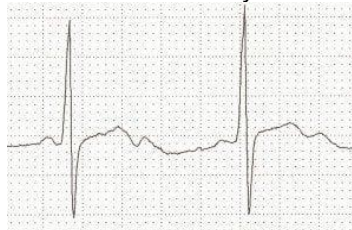
Wellens Pattern B (Type 2)

Wellens Pattern B (Type 2)

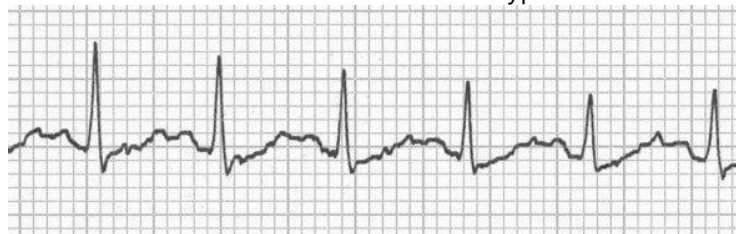
'Camel hump' T waves

'Camel hump' T waves is a term used by Amal Mattu to describe T-waves that have a double peak. There are two causes for camel hump T waves:

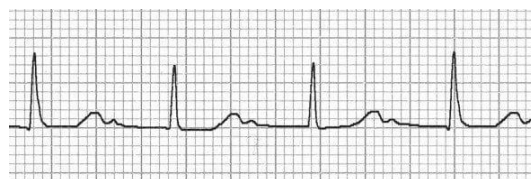- **Prominent U waves** fused to the end of the T wave, as seen in severe hypokalaemia
- **Hidden P waves** embedded in the T wave, as seen in sinus tachycardia and various types of heart block



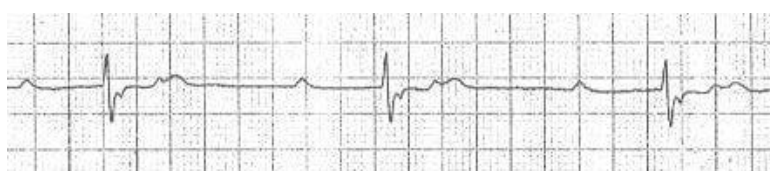
Prominent U waves due to severe hypokalaemia



Hidden P waves in sinus tachycardia



Hidden P waves in marked 1st degree heart block



Hidden P waves in 2nd degree heart block with 2:1 conduction

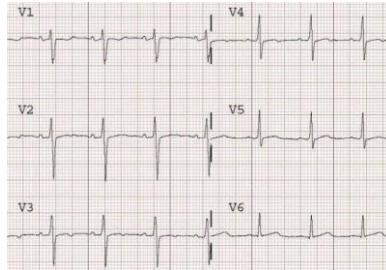
Flattened T waves

Flattened T waves are a non-specific finding, but may represent

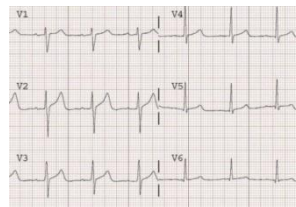
- Ischaemia (if dynamic or in contiguous leads) or
- Electrolyte abnormality, e.g. hypokalaemia (if generalised)

Ischaemia

Dynamic T-wave flattening due to anterior ischaemia (above). T waves return to normal once the ischaemia resolves (below).



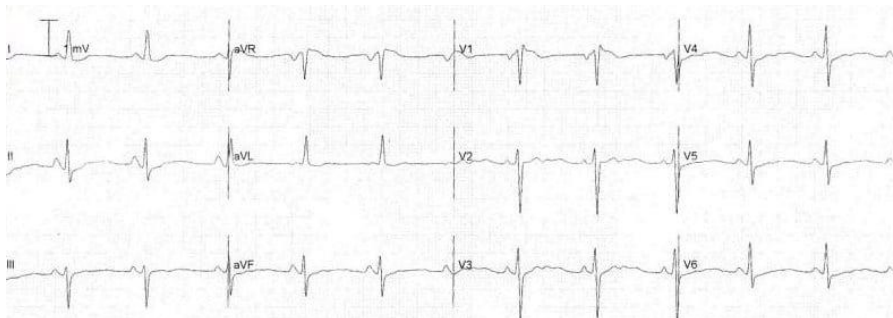
Dynamic T wave flattening due to anterior ischaemia



T waves return to normal as ischaemia resolves

HYPOKALAEMIA

Note global T-wave flattening in hypokalaemia associated with prominent U waves in the anterior leads (V2 and V3).



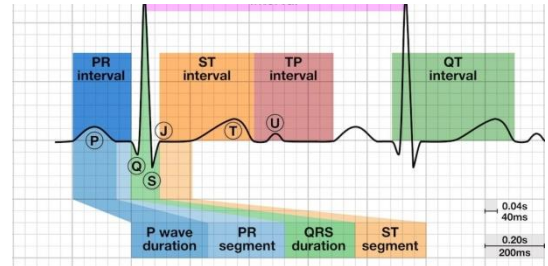
TP SEGMENT

The TP segment is the portion of the ECG from the end of the T wave to the beginning of the P wave.

This segment should always be at baseline and is used as a reference to determine whether the ST segment is elevated or depressed, as there are no specific disease conditions that elevate or depress the TP segment.

During states of tachycardia, the TP segment is shortened and may be difficult to visualize altogether. It is good to examine the TP segment closely for the presence of U waves or atrial activity that could indicate pathology.

QT INTERVAL

*Definition*

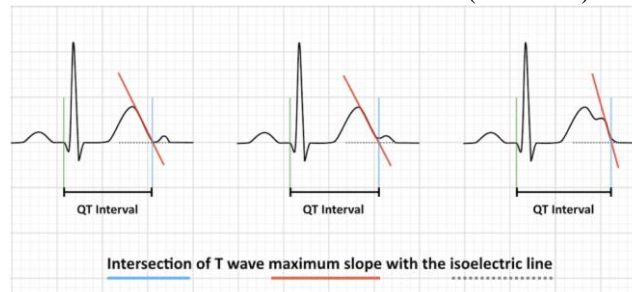
- Time from the start of the Q wave to the end of the T wave
- Represents time taken for ventricular depolarisation and repolarisation, effectively the period of ventricular systole from ventricular isovolumetric contraction to isovolumetric relaxation

THE QT INTERVAL IS INVERSELY PROPORTIONAL TO HEART RATE:

- The QT interval *shortens* at faster heart rates
- The QT interval *lengthens* at slower heart rates
- An abnormally prolonged QT is associated with an increased risk of ventricular arrhythmias, especially Torsades de Pointes
- Congenital short QT syndrome has been found to be associated with an increased risk of paroxysmal atrial and ventricular fibrillation and sudden cardiac death

HOW TO MEASURE THE QT INTERVAL

- The QT interval is usually measured in either lead II or V5-6, however the lead with the longest measurement should be used
- Several successive beats should be measured, with the maximum interval taken
- Large U waves (> 1mm) that are fused to the T wave should be included in the measurement
- Smaller U waves and those that are separate from the T wave should be excluded
- The *maximum slope intercept method* is used to define the end of the T wave (see below)



Left, middle: Smaller U waves and those that are separate from the T wave should be excluded from measurements

Right: Large U waves that are fused to the T wave should be included in measurements

The QT interval is defined from the beginning of the QRS complex to the end of the T wave. The maximum slope intercept method defines the end of the T wave as the intercept between the isoelectric line with the tangent drawn through the maximum down slope of the T wave (left).

When notched T waves are present (right), the QT interval is measured from the beginning of the QRS complex to the intersection point between the isoelectric line and the tangent drawn from the maximum down slope of the second notch.

CORRECTED QT INTERVAL (QTc)

- The corrected QT interval (QTc) *estimates* the QT interval at a standard heart rate of 60 bpm
- This allows comparison of QT values over time at different heart rates and improves detection of patients at increased risk of arrhythmias

There are multiple formulas used to estimate QTc. It is not clear which formula is the most useful:

- Bazett formula: $QT_c = QT / \sqrt{RR}$
- Fridericia formula: $QT_c = QT / RR^{1/3}$

- **Framingham formula:** $QT_c = QT + 0.154 (1 - RR)$
- **Hodges formula:** $QT_c = QT + 1.75 (\text{heart rate} - 60)$

Note: The RR interval is given in seconds (RR interval = 60 / heart rate).

- Bazett and Fridericia are logarithmic corrections whereas Hodges and Framingham are linear correction formulae
 - Henry Cuthbert Bazett derived his formula in 1920. Bazett formula is the most commonly used due to its simplicity. It over-corrects at heart rates > 100 bpm and under-corrects at heart rates < 60 bpm, but provides an adequate correction for heart rates ranging from 60 – 100 bpm
 - Louis Sigurd Fridericia derived his formula in 1920 from 50 healthy individuals aged 3 to 81 years old. Fridericia formula is the observed QT interval divided by cube root of RR interval, in seconds
 - Charbit B et al studied 108 patients and found that automatic QT correction using Bazett formula had a sensitivity for detection of QT prolongation of 54% while automatic QT correction using Fridericia formula had 100% sensitivity
 - At heart rates outside of the 60 – 100 bpm range, the Fridericia or Framingham corrections are more accurate and should be used instead [Framingham heart study, 1992]
 - If an ECG is fortuitously captured while the patient's heart rate is 60 bpm, the absolute QT interval should be used instead!
- Fortunately, there are now multiple phone apps that will calculate QTc for you, for example MDCalc.com has a quick and easy QTc calculator that is free to use.

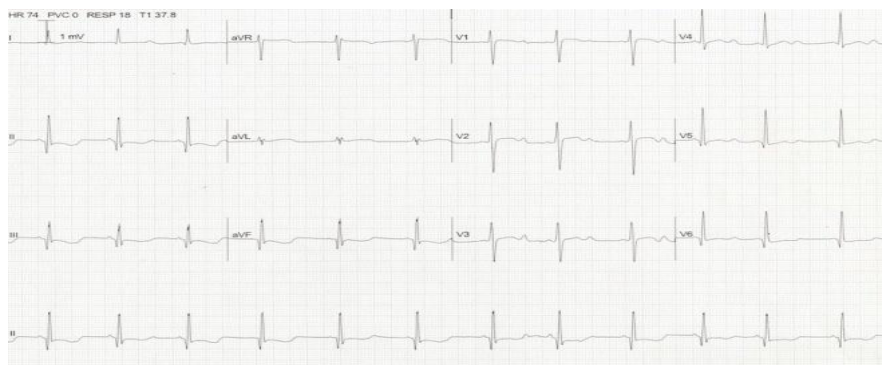
NORMAL QTc VALUES

- QTc is prolonged if > 440ms in men or > 460ms in women
- QTc > 500 is associated with an increased risk of torsades de pointes
- QTc is abnormally short if < 350ms
- A useful rule of thumb is that a normal QT is less than half the preceding RR interval

Causes of a prolonged QTc (>440ms)

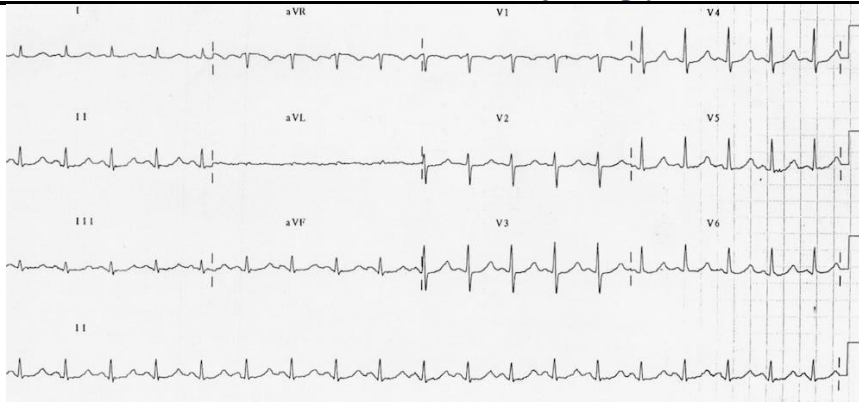
- Hypokalaemia
- Hypomagnesaemia
- Hypocalcaemia
- Hypothermia
- Myocardial ischemia
- ROSC Post-cardiac arrest
- Raised intracranial pressure
- Congenital long QT syndrome
- Medications/Drugs

HYPOKALAEMIA



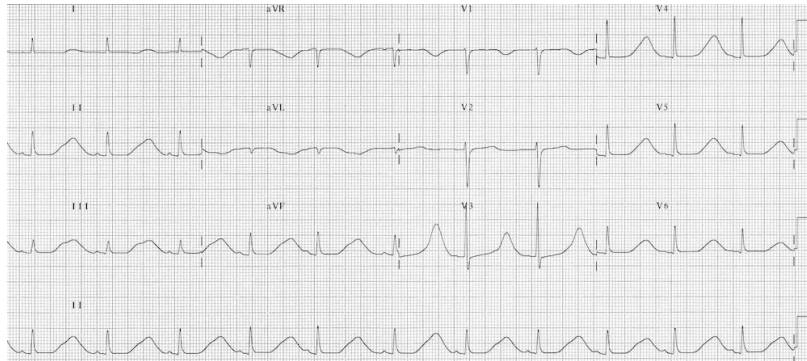
- Apparent QTc 500ms
- There are prominent U waves in precordial leads
- This patient had a K of 1.9
- Hypokalaemia causes apparent QTc prolongation in the limb leads (due to T-U fusion) with prominent U waves in the precordial leads.

HYPOMAGNESAEMIA



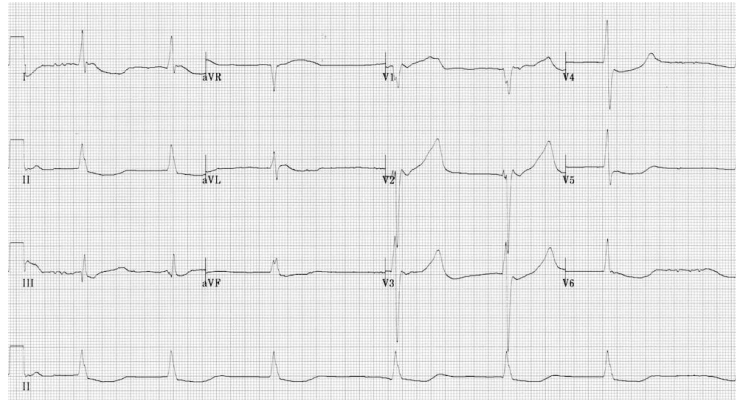
- QTc 510 ms secondary to hypomagnesaemia
-

- Hypocalcaemia



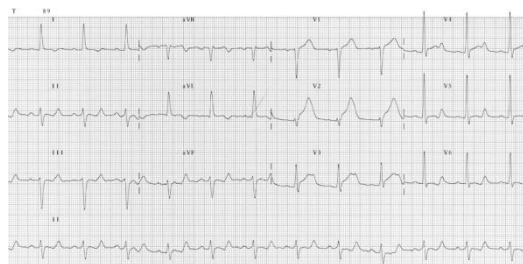
- QTc 510ms due to hypocalcaemia
- Hypocalcaemia typically prolongs the ST segment, leaving the T wave unchanged

HYPOTHERMIA

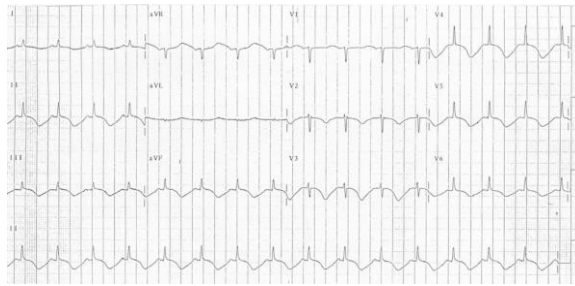


- QTc 620 ms due to severe hypothermia
- Severe hypothermia can cause marked QTc prolongation, often in association with bradyarrhythmias (especially slow AF), Osborn waves and shivering artefact

MYOCARDIAL ISCHAEMIA

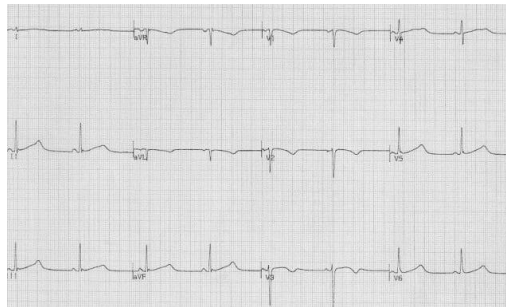


- QTc 495 ms due to hyperacute MI
- Myocardial ischemia tends to produce a modest increase in the QTc, in the 450-500 ms range
- This may be useful in distinguishing hyperacute MI from benign early repolarization (both may produce similar hyperacute T waves, but benign early repolarisation (BER) will usually have a *normal* QTc)



- QTc 630ms with widespread T wave inversion due to subarachnoid haemorrhage
- A sudden rise in intracranial pressure (e.g. due to subarachnoid haemorrhage) may produce characteristic T wave changes ('cerebral T waves'): widespread, deep T wave inversions with a prolonged QTc

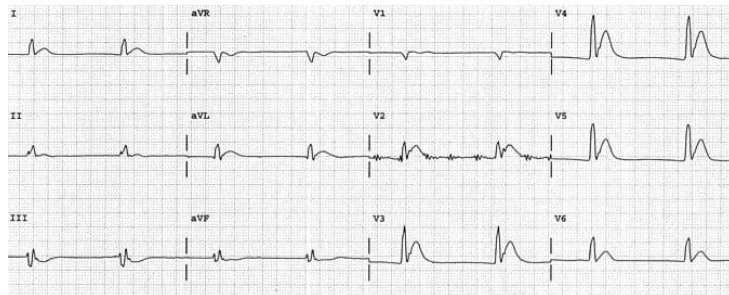
CONGENITAL LONG QT SYNDROME



- QTc 550ms due to congenital long QT syndrome
- There are several congenital disorders of ion channels that produce a long QT syndrome and are associated with increased risk of torsades de pointes and sudden cardiac death

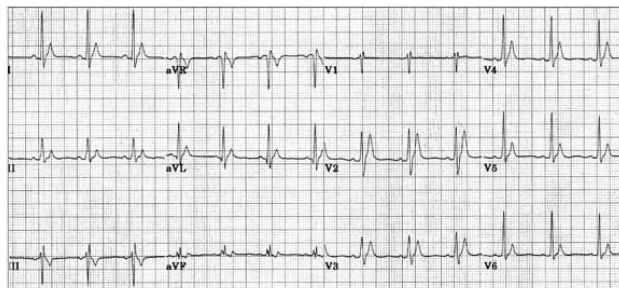
Causes of a short QTc (<350ms)

- Hypercalcaemia
- Congenital short QT syndrome
- Digoxin effect
- Hypercalcaemia



- Marked shortening of the QTc (260ms) due to hypercalcaemia
- Hypercalcaemia leads to shortening of the ST segment and may be associated with the appearance of Osborne waves

CONGENITAL SHORT QT SYNDROME

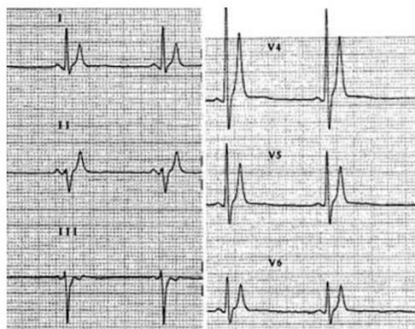


- Very short QTc (280ms) with tall, peaked T waves due to congenital short QT syndrome
- Congenital short QT syndrome (SQTS) is an autosomal dominant inherited disorder of potassium channels associated with an increased risk of paroxysmal atrial and ventricular fibrillation and sudden cardiac death
- The main ECG changes are very short QTc (<300-350ms) with tall, peaked T waves

SHORT QT SYNDROME MAY BE SUGGESTED BY THE PRESENCE OF:

- Lone atrial fibrillation in young adults

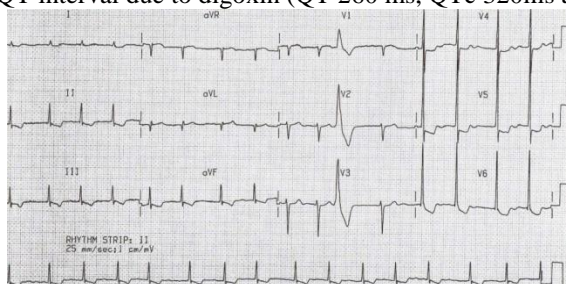
- Family member with a short QT interval
- Family history of sudden cardiac death
- ECG showing QTc < 350 ms with tall, peaked T waves
- Failure of the QT interval to increase as the heart rate slows



Very short QT (< 300ms) with peaked T waves in two patients with SQTs

DIGOXIN

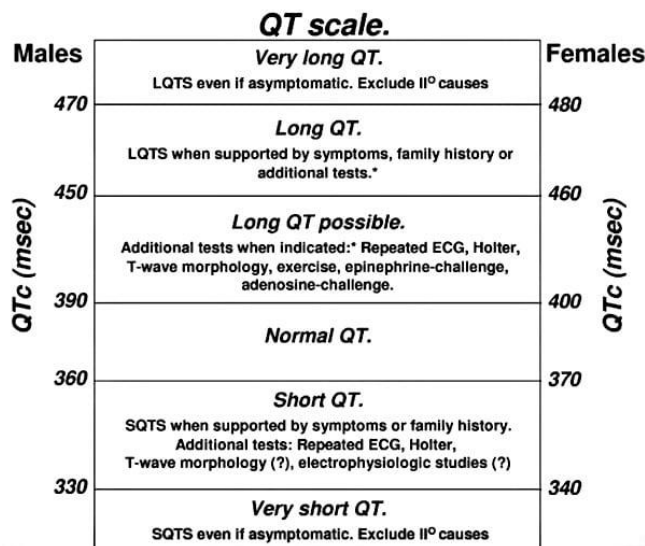
Short QT interval due to digoxin (QT 260 ms, QTc 320ms approx)



Digoxin produces a relative shortening of the QT interval, along with downward sloping ST segment depression in the lateral leads (‘reverse tick’ appearance), widespread T-wave flattening and inversion, and a multitude of arrhythmias (ventricular ectopy, atrial tachycardia with block, sinus bradycardia, regularized AF, any type of AV block).

QT interval scale

Viskin (2009) proposes the use of a ‘QT interval scale’ to aid diagnosis of patients with short and long QT syndromes (once reversible causes have been excluded):

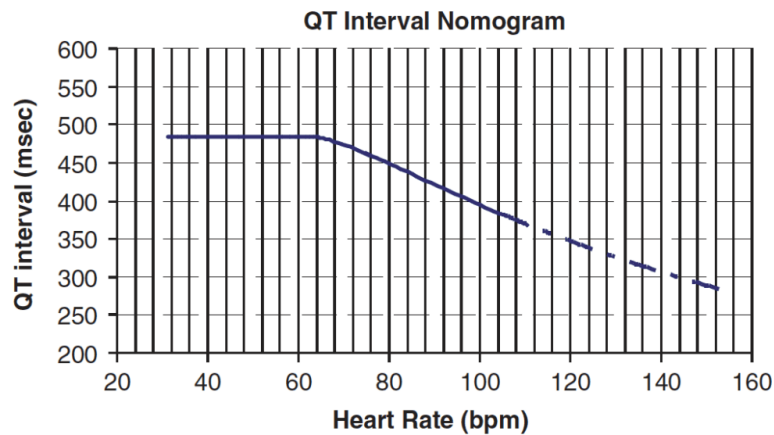


Drug-induced QT-Prolongation and Torsades

In the context of acute poisoning with QT-prolonging agents, the risk of TdP is better described by the *absolute* rather than *corrected* QT.

- More precisely, the risk of TdP is determined by considering both the **absolute QT interval** and the **simultaneous heart rate** (i.e. on the same ECG tracing).
- These values are then plotted on the **QT nomogram** (developed by Chan et al) to determine whether the patient is at risk of TdP.

- The QT nomogram is a clinically relevant risk assessment tool that predicts arrhythmogenic risk for drug-induced QT prolongation can be used for risk stratification
- A QT interval-heart rate pair that plots *above the line* indicates the patient is at risk of TdP.

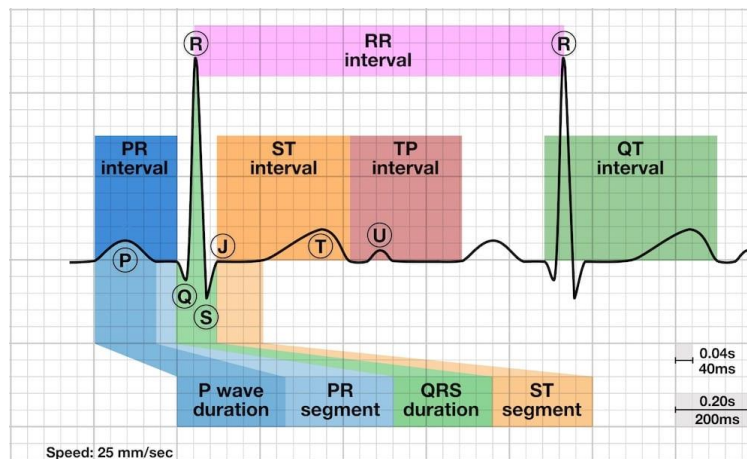


THE ST SEGMENT

S-T Segment

The **ST segment** is the flat, isoelectric section of the ECG between the end of the S wave (the J point) and the beginning of the T wave.

- The ST Segment represents the interval between ventricular depolarization and repolarization.
- The most important cause of ST segment abnormality (elevation or depression) is **myocardial ischaemia** or **infarction**.



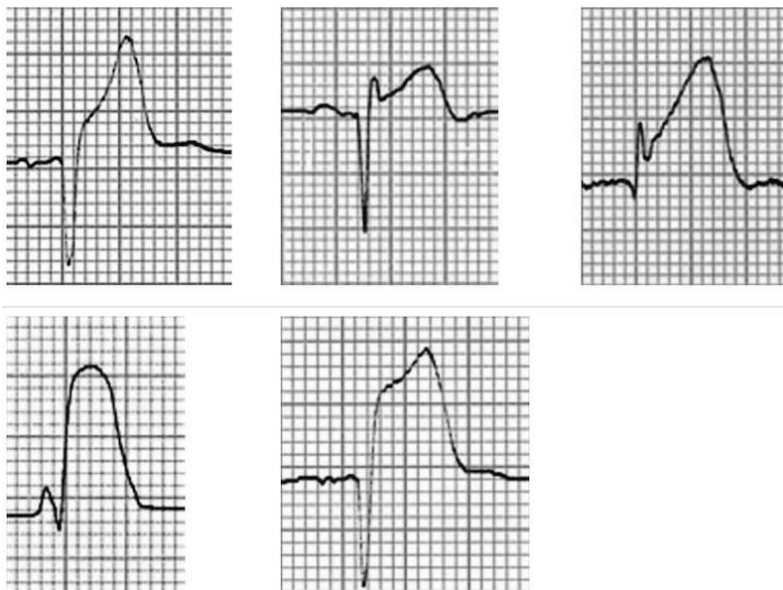
Causes of ST Segment Elevation

- Acute myocardial infarction
- Coronary vasospasm (Prinzmetal's angina)
- Pericarditis
- Benign early repolarization
- Left bundle branch block
- Left ventricular hypertrophy
- Ventricular aneurysm
- Brugada syndrome
- Ventricular paced rhythm
- Raised intracranial pressure
- Takotsubo Cardiomyopathy

Morphology of the Elevated ST segment

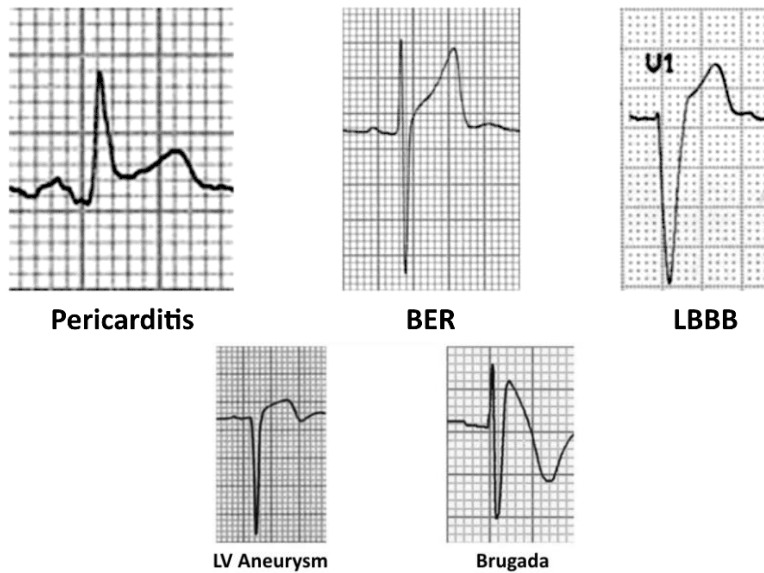
I Lateral	aVR	V1 Septal	V4 Anterior
II Inferior	aVL Lateral	V2 Septal	V5 Lateral
III Inferior	aVF Inferior	V3 Anterior	V6 Lateral
SITE		FACING	RECIPROCAL
SEPTAL		V1, V2	NONE
ANTERIOR		V3, V4	NONE
ANTEROSEPTAL		V1, V2, V3, V4	NONE
LATERAL		I, aVL, V5, V6	II, III, aVF
ANTEROLATERAL		I, aVL, V3, V4, V5, V6	II, III, aVF
INFERIOR		II, III, aVF	I, aVL
POSTERIOR		NONE	V1, V2, V3, V4

Myocardial Infarction



Acute STEMI may produce ST elevation with either concave, convex or obliquely straight morphology.

ST Segment Morphology in Other Conditions



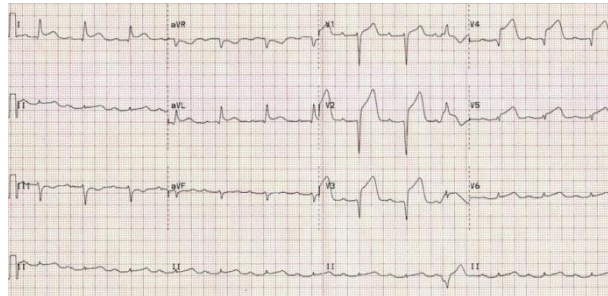
Patterns of ST Elevation

ACUTE ST ELEVATION MYOCARDIAL INFARCTION (STEMI)

ST segment elevation and Q-wave formation in contiguous leads. Follow the links above to find out more about the different STEMI patterns.:

- Septal (V1-2)
- Anterior (V3-4)
- Lateral (I + aVL, V5-6)
- Inferior (II, III, aVF)
- Right ventricular (V1, V4R)
- Posterior (V7-9)

There is usually **reciprocal ST depression** in the electrically opposite leads. For example, STE in the high lateral leads I + aVL typically produces reciprocal ST depression in lead III (see example below).

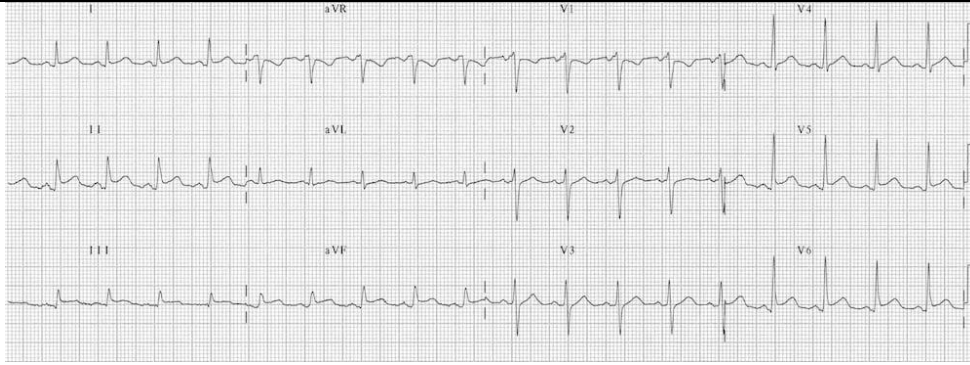


Coronary Vasospasm (Prinzmetal's angina)

- This causes a pattern of ST elevation that is very similar to acute STEMI — i.e. localised ST elevation with reciprocal ST depression occurring during episodes of chest pain.
- However, unlike acute STEMI the ECG changes are transient, reversible with vasodilators and not usually associated with myocardial necrosis.
- It may be impossible to differentiate these two conditions based on the ECG alone.

Pericarditis

Acute Pericarditis causes widespread concave ("saddleback") ST segment elevation with PR segment depression in multiple leads, typically involving I, II, III, aVF, aVL, and V2-6.

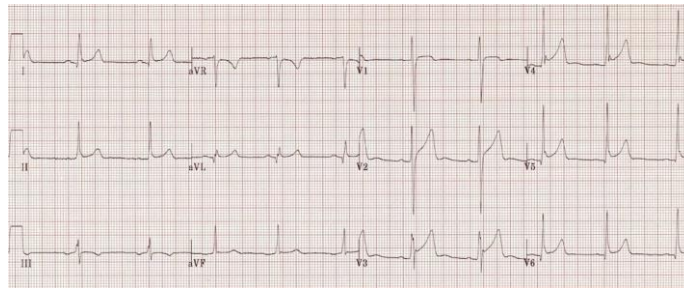


- Concave “saddleback” ST elevation in leads I, II, III, aVF, V5-6 with depressed PR segments.
- There is reciprocal ST depression and PR elevation in leads aVR and V1.
- Spodick’s sign was first described by David H. Spodick in 1974 as a downward sloping TP segment with specificity for acute pericarditis.

Benign Early Repolarization

Benign Early Repolarization (BER) causes mild ST elevation with tall T-waves mainly in the precordial leads. BER is a normal variant commonly seen in young, healthy patients. There is often notching of the J-point — the “fish-hook” pattern.

The ST changes may be more prominent at slower heart rates and disappear in the presence of tachycardia.

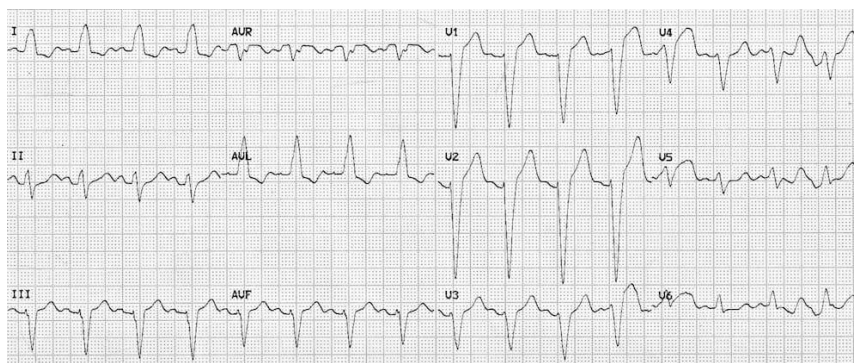


There is slight concave ST elevation in the precordial and inferior leads with notching of the J-point (the “fish-hook” pattern)

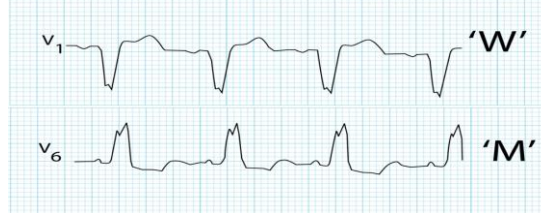Left Bundle Branch Block (LBBB)

In Left bundle branch block (LBBB), the ST segments and T waves show “appropriate discordance” — i.e. they are directed opposite to the main vector of the QRS complex.

This produces ST elevation and upright T waves in leads with a negative QRS complex (dominant S wave), while producing ST depression and T wave inversion in leads with a positive QRS complex (dominant R wave).

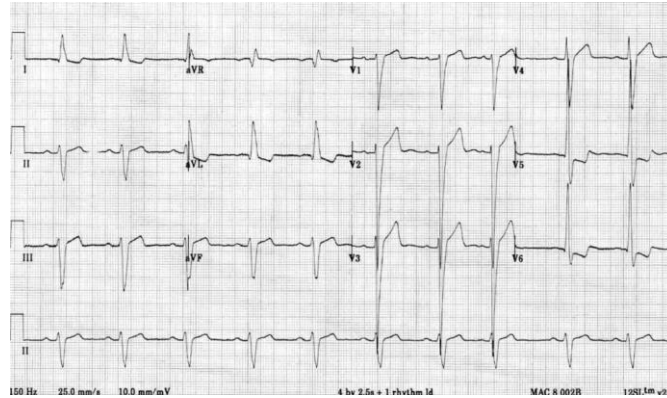


- Note the ST elevation in leads with deep S waves — most apparent in V1-3.
- Also note the ST depression in leads with tall R waves — most apparent in I and aVL.



Left Ventricular Hypertrophy (LVH)

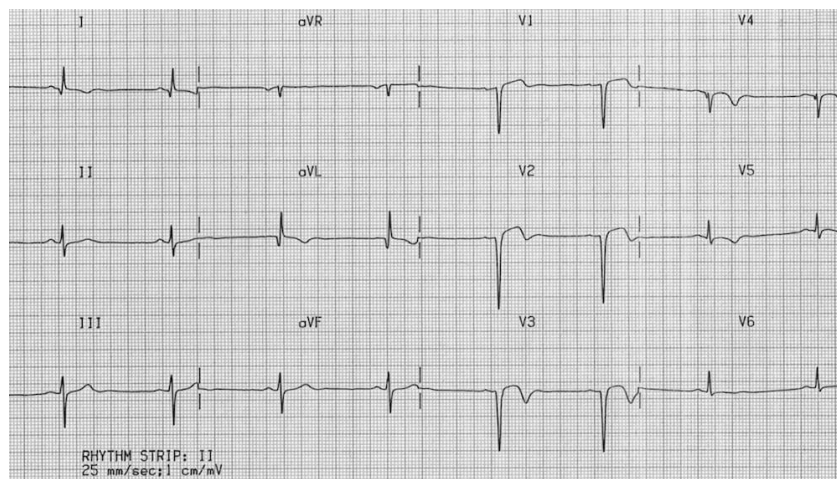
Left Ventricular Hypertrophy (LVH) causes a similar pattern of repolarization abnormalities as LBBB, with ST elevation in the leads with deep S-waves (usually V1-3) and ST depression/T-wave inversion in the leads with tall R waves (I, aVL, V5-6).



- Left axis deviation
- Deep S waves with ST elevation in V1-3
- ST depression and T-wave inversion in the lateral leads V5-6

Ventricular Aneurysm

This is an ECG pattern of Ventricular Aneurysm – residual ST elevation and deep Q waves seen in patients with previous myocardial infarction. It is associated with extensive myocardial damage and paradoxical movement of the left ventricular wall during systole.

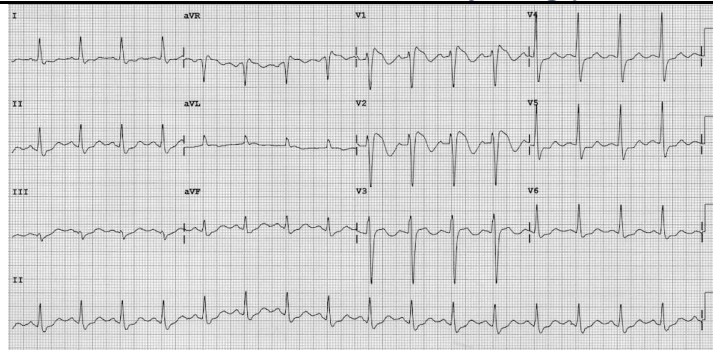


- There is ST elevation with deep Q waves and inverted T waves in V1-3.
- This pattern suggests the presence of a left ventricular aneurysm due to a prior anteroseptal MI.

Brugada Syndrome

Brugada Syndrome is an inherited channelopathy (a disease of myocardial sodium channels) that leads to paroxysmal ventricular arrhythmias and sudden cardiac death in young patients.

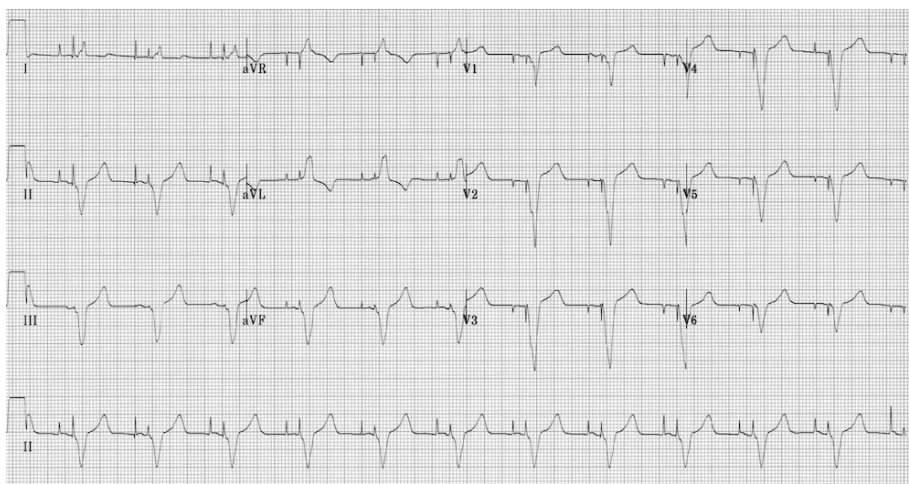
The tell-tale sign on the resting ECG is the "Brugada sign" — ST elevation and partial RBBB in V1-2 with a "coved" morphology.



There is ST elevation and partial RBBB in V1-2 with a coved morphology — the “Brugada sign”.

Ventricular Paced Rhythm

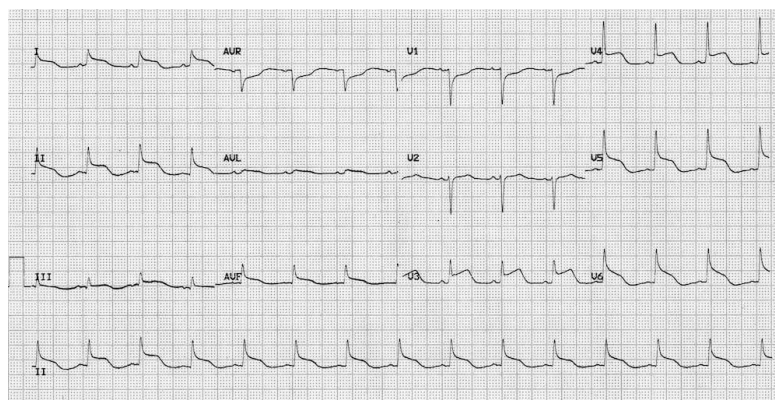
Ventricular pacing (with a pacing wire in the right ventricle) causes ST segment abnormalities identical to that seen in LBBB. There is *appropriate discordance*, with the ST segment and T wave directed opposite to the main vector of the QRS complex.



Raised Intracranial Pressure

Raised Intracranial Pressure (ICP) (e.g. due to intracranial haemorrhage, traumatic brain injury) may cause ST elevation or depression that simulates myocardial ischaemia or pericarditis.

More commonly, raised ICP is associated with widespread, deep T-wave inversions (“cerebral T waves”).

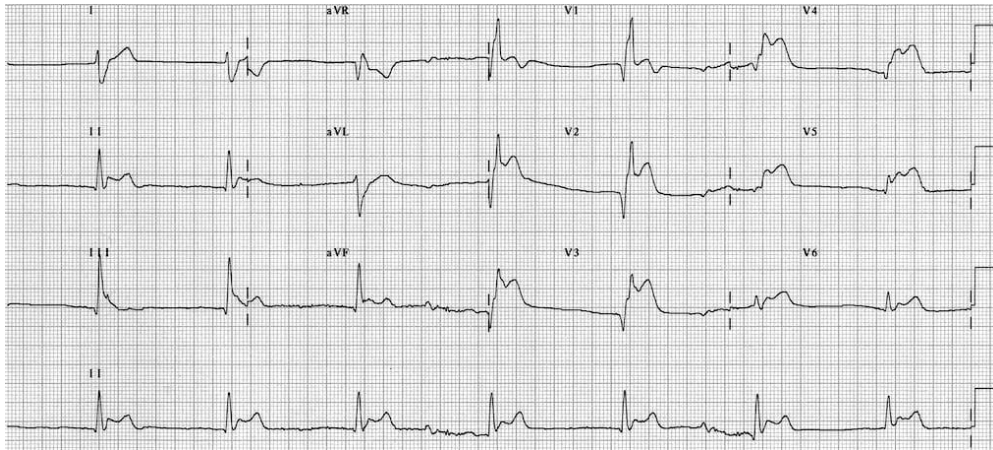


Widespread ST elevation with concave (pericarditis-like) morphology in a patient with severe traumatic brain injury.

Takotsubo Cardiomyopathy

Takotsubo Cardiomyopathy: A STEMI mimic producing ischaemic chest pain, ECG changes +/- elevated cardiac enzymes with characteristic regional wall motion abnormalities on echocardiography.

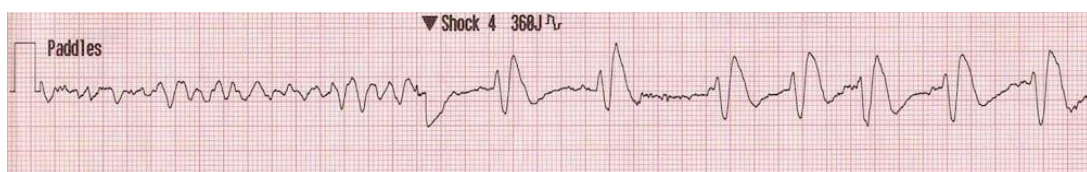
Typically occurs in the context of severe emotional distress ("broken heart syndrome"). Commonly associated with new ECG changes (ST elevation or T wave inversion) or moderate troponin rise.



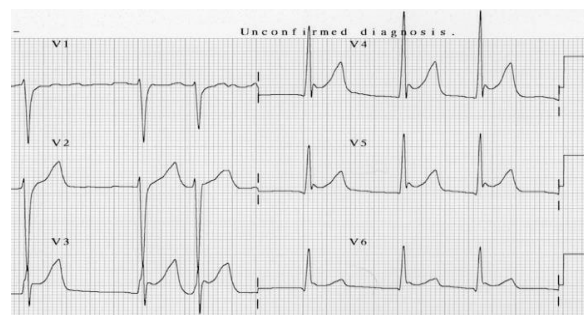
Less Common Causes of ST segment Elevation

- Pulmonary embolism and acute cor pulmonale (usually in lead III)
- Acute aortic dissection (classically causes inferior STEMI due to RCA dissection)
- Hyperkalaemia
- Sodium-channel blocking drugs (secondary to QRS widening)
- J-waves (hypothermia, hypercalcaemia)
- Following electrical cardioversion
- Others: Cardiac tumour, myocarditis, pancreas or gallbladder disease

Transient ST elevation after DC cardioversion from VF



J waves in hypothermia simulating ST elevation



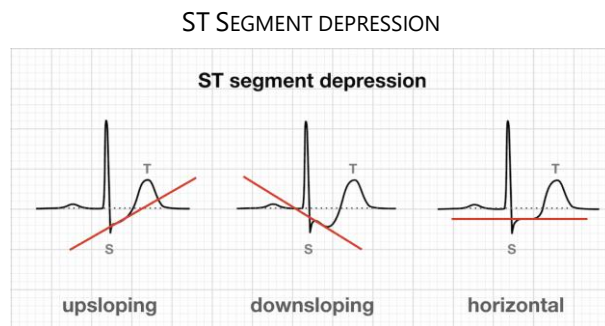
Causes of ST Depression

- Myocardial ischaemia / NSTEMI
- Reciprocal change in STEMI/Posterior MI

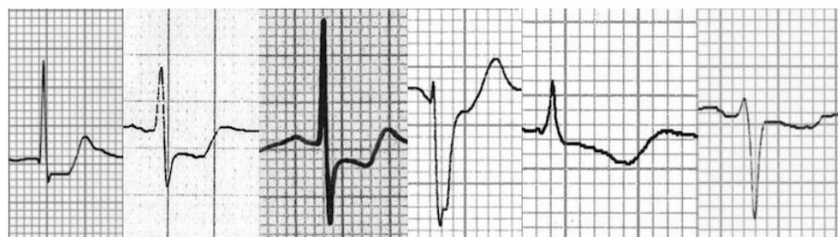
- Digoxin effect
- Hypokalaemia
- Supraventricular tachycardia
- Right bundle branch block
- Right ventricular hypertrophy
- Left bundle branch block
- Left ventricular hypertrophy
- Ventricular paced rhythm

Morphology of ST Depression

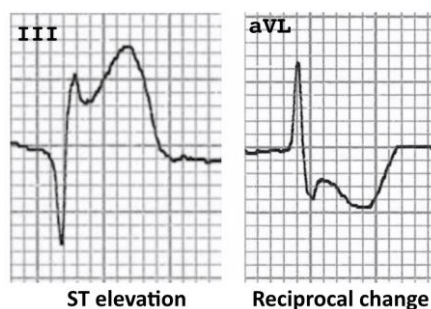
- ST depression can be either upsloping, downsloping, or horizontal.
- Horizontal or downsloping ST depression ≥ 0.5 mm at the J-point in ≥ 2 contiguous leads indicates myocardial ischaemia (according to the 2007 Task Force Criteria).
- Upsloping ST depression in the precordial leads with prominent De Winter T waves is highly specific for occlusion of the LAD.
- Reciprocal change has a morphology that resembles “upside down” ST elevation and is seen in leads electrically opposite to the site of infarction.
- Posterior MI manifests as horizontal ST depression in V1-3 and is associated with upright T waves and tall R waves.



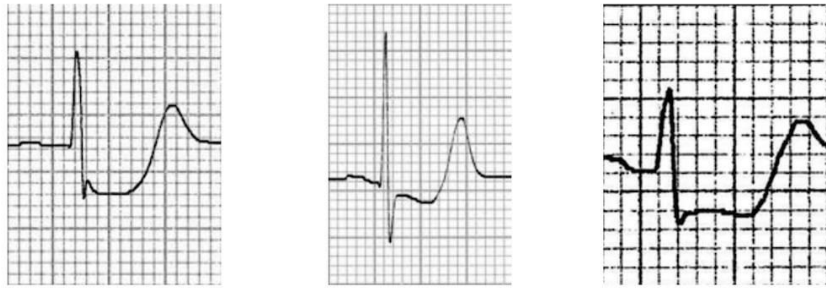ST segment morphology in myocardial ischaemia



Reciprocal change



ST segment morphology in posterior MI

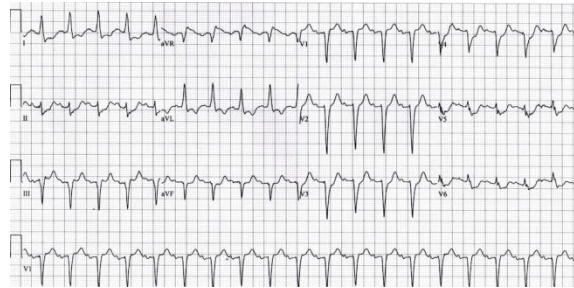


Patterns of ST depression

Myocardial Ischaemia

ST depression due to subendocardial ischaemia may be present in a variable number of leads and with variable morphology. It is often most prominent in the left precordial leads V4-6 plus leads I, II and aVL.

Widespread ST depression with ST elevation in aVR is seen in left main coronary artery occlusion and severe triple vessel disease.

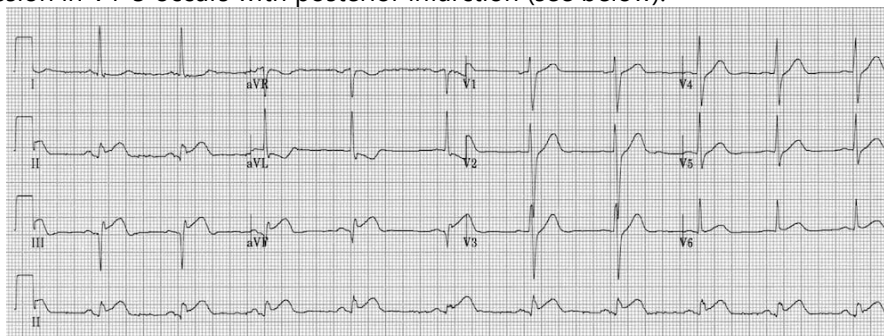


NB. ST depression localised to the inferior or high lateral leads is more likely to represent reciprocal change than subendocardial ischaemia. The corresponding ST elevation may be subtle and difficult to see, but should be sought. This concept is discussed further here.

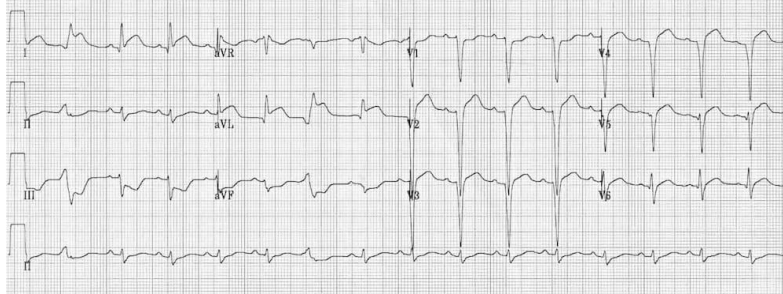
Reciprocal Change

ST elevation during acute STEMI is associated with simultaneous ST depression in the electrically opposite leads:

- Inferior STEMI produces reciprocal ST depression in aVL (\pm lead I).
- Lateral or anterolateral STEMI produces reciprocal ST depression in III and aVF (\pm lead II).
- Reciprocal ST depression in V1-3 occurs with posterior infarction (see below).



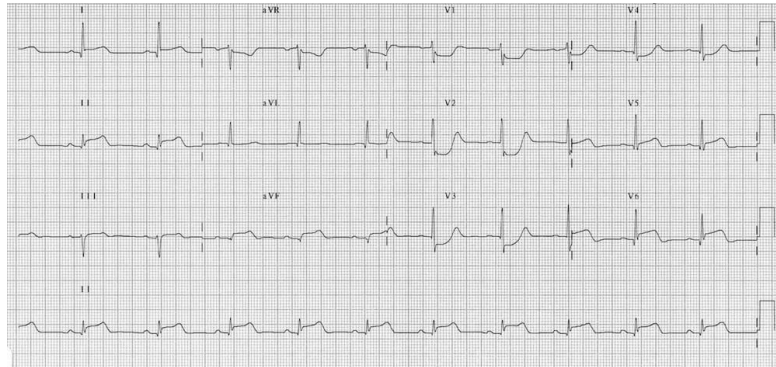
- Reciprocal ST depression in aVL with inferior STEMI



- Reciprocal ST depression in III and aVF with high lateral STEMI

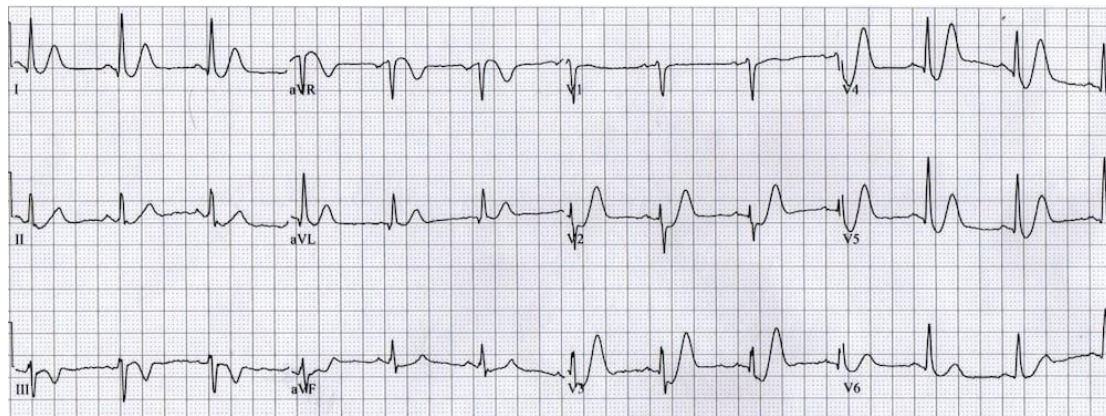
Posterior Myocardial Infarction

Acute posterior STEMI causes ST depression in the anterior leads V1-3, along with dominant R waves (“Q-wave equivalent”) and upright T waves. There is ST elevation in the posterior leads V7-9.



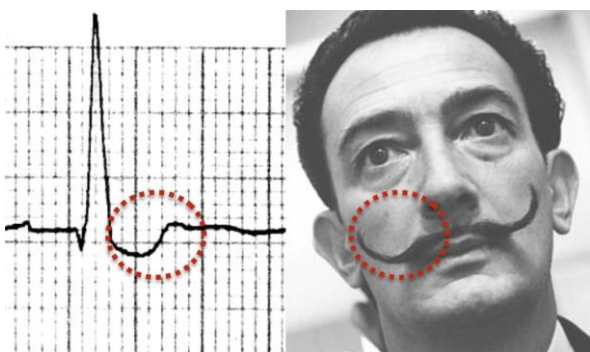
De Winter T Waves

De Winter T waves: a pattern of up-sloping ST depression with symmetrically peaked T waves in the precordial leads is considered to be a STEMI equivalent, and is highly specific for an acute occlusion of the LAD.



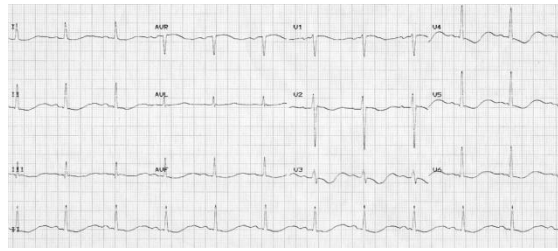
Digoxin Effect

Digoxin Effect: Treatment with digoxin causes downsloping ST depression with a “sagging” morphology, reminiscent of Salvador Dali’s moustache.



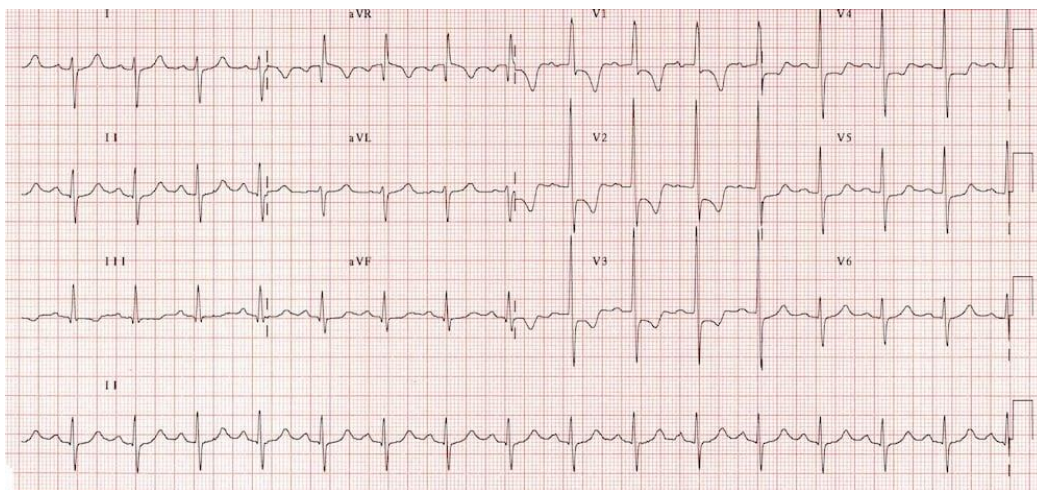
Hypokalaemia

Hypokalaemia causes widespread downsloping ST depression with T-wave flattening/inversion, prominent U waves and a prolonged QU interval.



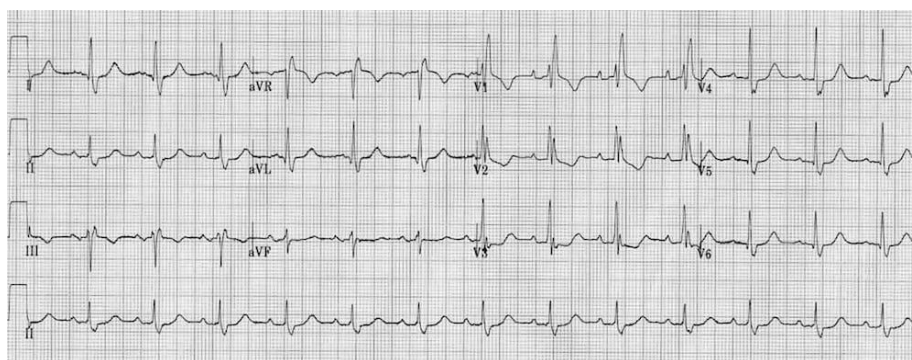
Right ventricular hypertrophy (RVH)

Right ventricular hypertrophy (RVH) causes ST depression and T-wave inversion in the right precordial leads V1-3.



Right Bundle Branch Block (RBBB)

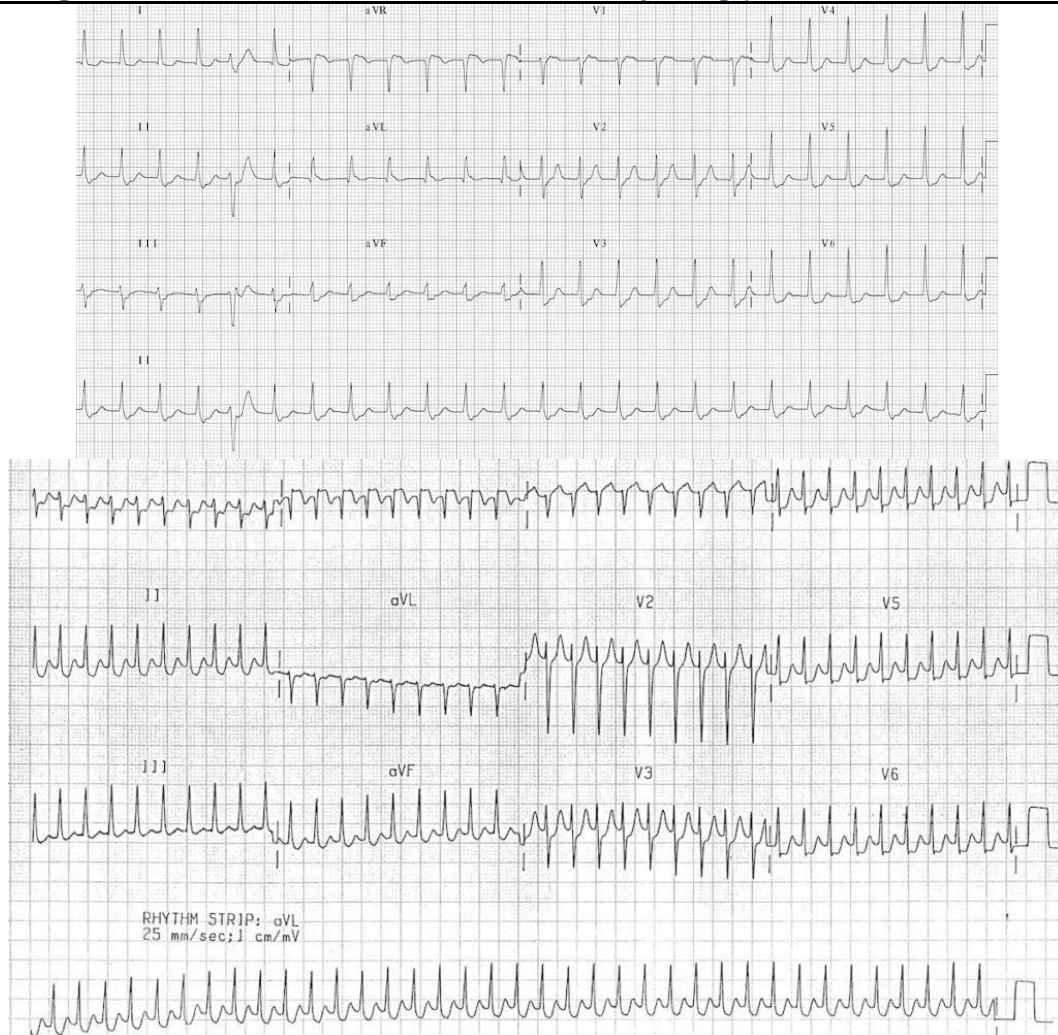
Right Bundle Branch Block (RBBB) may produce a similar pattern of repolarisation abnormalities to RVH, with ST depression and T wave inversion in V1-3.



Supraventricular tachycardia (SVT)

Supraventricular tachycardia (e.g. AVNRT) typically causes widespread horizontal ST depression, most prominent in the left precordial leads (V4-6).

This rate-related ST depression does not necessarily indicate the presence of myocardial ischaemia, provided that it resolves with treatment.



U wave

U wave Overview

The U wave is a small (0.5 mm) deflection immediately following the T wave

- U wave is usually in the same direction as the T wave.
- U wave is best seen in leads V2 and V3.

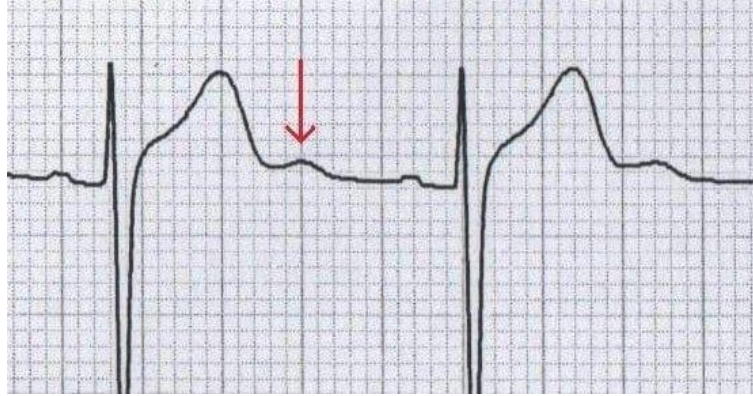
Source of the U wave

The source of the U wave is unknown. Three common theories regarding its origin are:

- Delayed repolarisation of Purkinje fibres
- Prolonged repolarisation of mid-myocardial "M-cells"
- After-potentials resulting from mechanical forces in the ventricular wall

Features of Normal U waves

- The U wave normally goes in the same direction as the T wave
- U -wave size is inversely proportional to heart rate: the U wave grows bigger as the heart rate slows down
- U waves generally become visible when the heart rate falls below 65 bpm
- The voltage of the U wave is normally < 25% of the T-wave voltage: disproportionately large U waves are abnormal
- Maximum normal amplitude of the U wave is 1-2 mm



Abnormalities of the U wave

- Prominent U waves
- Inverted U waves

Prominent U waves

U waves are described as prominent if they are

- **>1-2mm or 25% of the height of the T wave.**

Causes of prominent U waves

Prominent U waves **most commonly** found with:

- Bradycardia
- Severe hypokalaemia.

Prominent U waves **may** be present with:

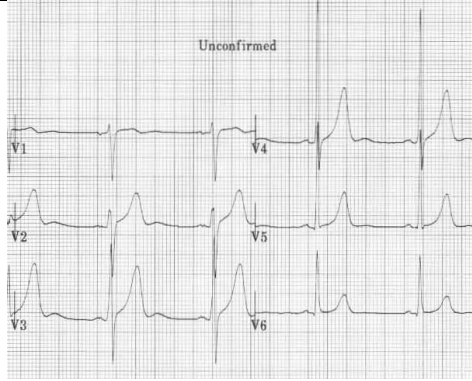
- Hypocalcaemia
- Hypomagnesaemia
- Hypothermia
- Raised intracranial pressure
- Left ventricular hypertrophy
- Hypertrophic cardiomyopathy

Drugs associated with prominent U waves:

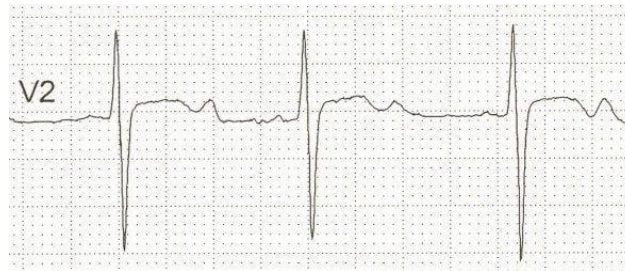
- Digoxin
- Phenothiazines (thioridazine)
- Class Ia antiarrhythmics (quinidine, procainamide)
- Class III antiarrhythmics (sotalol, amiodarone)

Note many of the conditions causing prominent U waves will also cause a long QT.

PROMINENT U WAVES DUE TO SINUS BRADYCARDIA

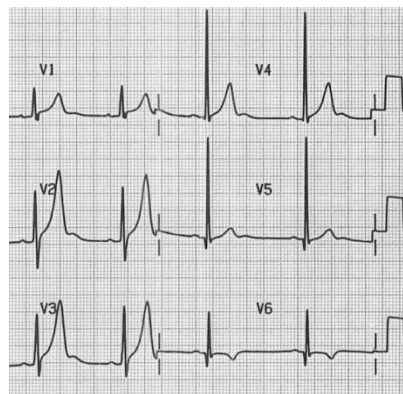


U WAVES ASSOCIATED WITH HYPOKALAEMIA

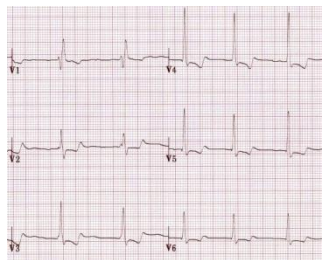


Prominent U waves in a patient with a K⁺ of 1.9

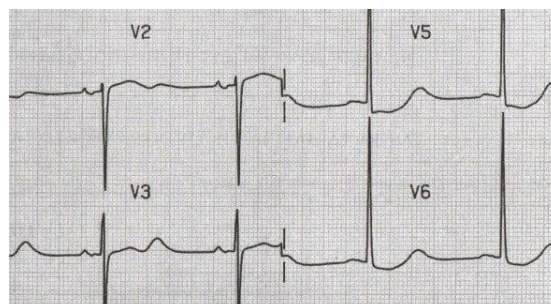
U WAVES ASSOCIATED WITH LEFT VENTRICULAR HYPERTROPHY



U WAVES ASSOCIATED WITH DIGOXIN USE



U WAVES ASSOCIATED WITH QUINIDINE USE



Inverted U waves

- U-wave inversion is abnormal (*in leads with upright T waves*)
- A negative U wave is highly specific for the presence of heart disease

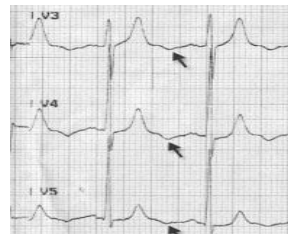
Common causes of inverted U waves

- Coronary artery disease
- Hypertension
- Valvular heart disease
- Congenital heart disease
- Cardiomyopathy
- Hyperthyroidism

In patients presenting with chest pain, inverted U waves:

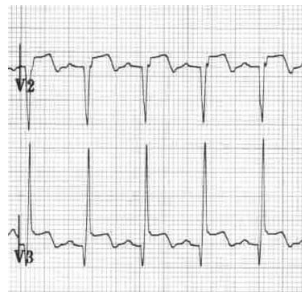
- Are a very specific sign of **myocardial ischaemia**
- May be the earliest marker of unstable angina and evolving myocardial infarction
- Have been shown to predict a $\geq 75\%$ stenosis of the LAD / LMCA and the presence of left ventricular dysfunction

UNSTABLE ANGINA

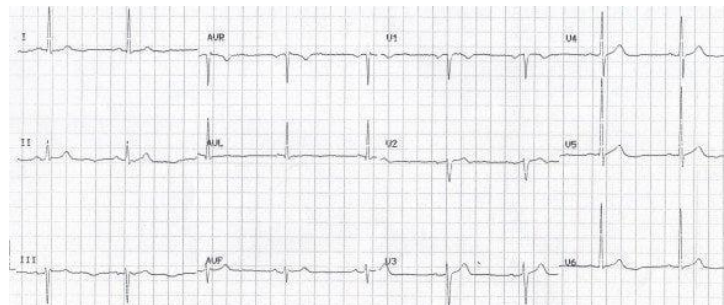


- Inverted U waves in a patient with unstable angina. Reproduced from Girish et al.

INVERTED U WAVES IN PRINZMETAL ANGINA



NSTEMI

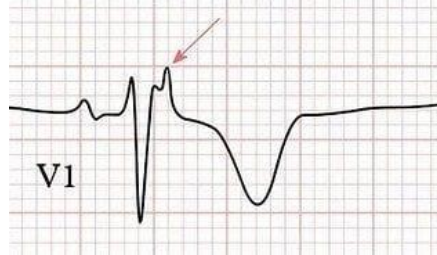


- Note the subtle U-wave inversion in the lateral leads (I, V5 and V6) in this patient with a NSTEMI; these were the only abnormal findings on his ECG.

Epsilon Wave*Epsilon Wave Definition*

- Small deflection ("blip" or "wigggle") buried in the end of the QRS complex

- On Standard 12-lead ECG (S-ECG), best seen in ST segment of V1 and V2, they are usually present in leads V1 through V4
- Caused by post-excitation of myocytes in the right ventricle
- Characteristic finding in patients with arrhythmogenic right ventricular dysplasia (ARVD)



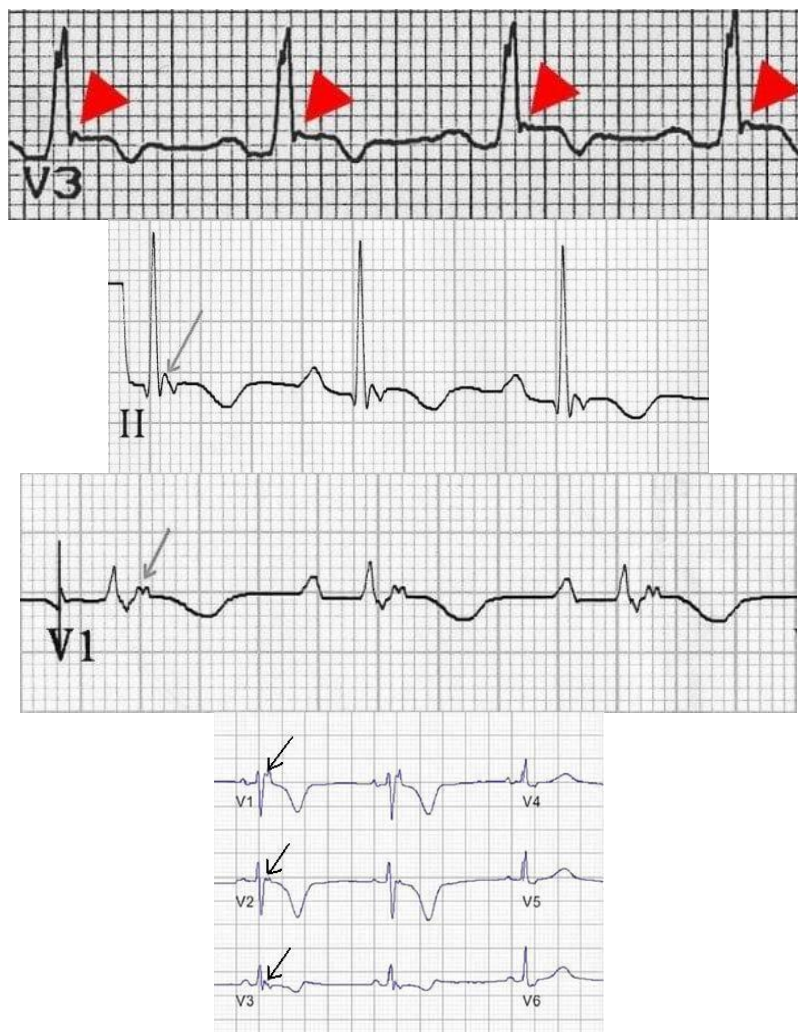
Epsilon wave in V1 due to RV conduction delay

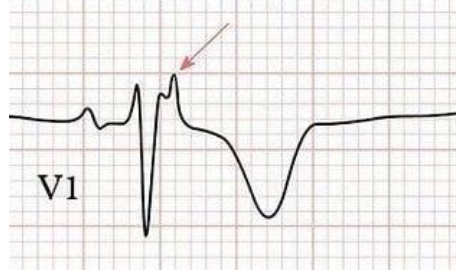
Epsilon waves are the most specific and characteristic finding in arrhythmogenic right ventricular dysplasia (ARVD). In ARVD, myocytes are replaced by fat, producing islands of viable myocytes in a sea of fat. This causes a delay in excitation of some of the myocytes of the right ventricle, producing a small “blip” seen during the ST segment of the ECG.

Epsilon waves have also been described in patients with:

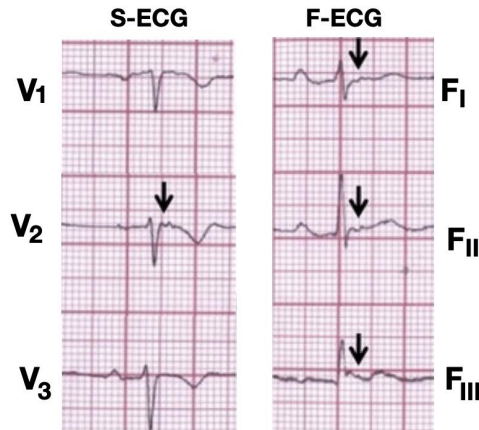
- Posterior myocardial infarction
- Right ventricular infarction
- Infiltrative disease
- Sarcoidosis

ECG EXAMPLES OF EPSILON WAVES





Fontaine lead



Comparison of S-ECG versus F-ECG in the ability to detect epsilon waves (arrows). Gottschalk et al 2014

The Fontaine lead placement increases sensitivity of detecting epsilon waves so that they are detected in three leads (F_I, F_{II}, F_{III}) rather than one lead in the regular placement.

HISTORY OF THE EPSILON WAVE

Guy Hugues Fontaine (1936-2018) was a French cardiologist and electrophysiologist. In 1977 he defined and named arrhythmogenic right ventricular dysplasia **ARVD**; the **epsilon wave**; and the **Fontaine lead** placement to best amplify the waves on an ECG

The term "epsilon" was nice, because it occurs in the Greek alphabet after delta; thus, delta represents the pre-excitation and epsilon the post-excitation phenomenon. In addition, epsilon is also used in mathematics to express a very small phenomenon...

Fontaine bipolar precordial leads (F-ECG) can be used to increase the sensitivity of epsilon wave detection. Leads are placed as shown:

- Right Arm (**RA**) over the manubrium;
- Left Arm (**LA**) over the xiphoid process;
- and Left Leg (**LL**) in the standard V₄ position (5th ICS MCL).

Instead of regular leads I, II, and III there are now three *bipolar* chest leads that are termed F_I, F_{II}, and F_{III} which record the potentials developed in the right ventricle, from the infundibulum to the diaphragm.

The vertical bipolar lead F_I, (similar to aV_F) magnifies the atrial potentials and can be used to record:

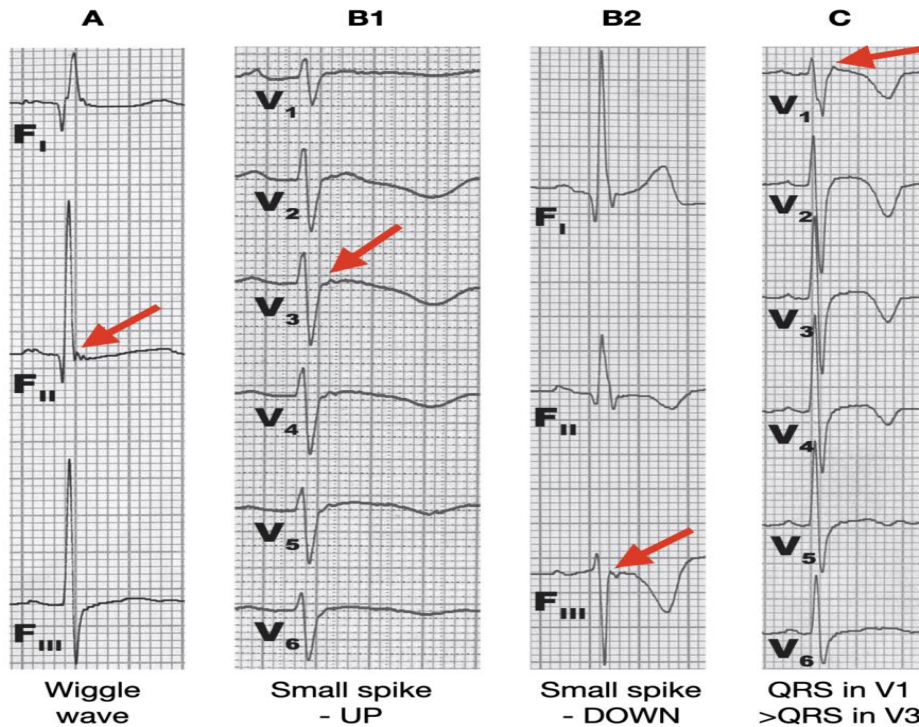
- epsilon waves;
- search for AV dissociation in ventricular tachycardia;
- and to study abnormal atrial rhythms when the P waves are too small on regular leads.

Fontaine bipolar precordial leads (F-ECG)

In 2010, Wang et al published their study on Epsilon waves detected by various electrocardiographic recording methods: in patients with arrhythmogenic right ventricular cardiomyopathy. In particular they compared the three ECG methods of S-ECG, R-ECG and F-ECG in known ARVD/C patients.

They identified 3 patterns of epsilon waves:

- (A) wiggle waves
- (B) small spike waves [B1 – spike upward; B2 – spike downward]
- (C) smooth potential waves with the QRS duration in V1 exceeding the QRS duration in V3 by at least 25ms.



Patterns of epsilon waves. Wang et al 2010

They found that

- The **duration and amplitude** of epsilon waves detected by F-ECG were **longer and larger** than those detected by the other 2 ECG recording methods.
- Epsilon waves are relatively low in sensitivity, manifesting themselves during S-ECG in only 20% to 25% of ARVC patients; and those waves are usually seen in leads V1 through V3.
- Epsilon waves were found in 38% of all patients using S-ECG and increased that to 50% by using F-ECG.
- The detection rate of epsilon waves using **combined methods** of ECG recording was significantly higher than that of S-ECG alone (S-ECG 38%; SF-ECG 56%; and SRF-ECG 66%, P=0.0039).

ARRHYTHMOGENIC RIGHT VENTRICULAR DYSPLASIA (ARVD)

The ECG changes in Arrhythmogenic Right Ventricular Dysplasia include:

- Epsilon wave (most specific finding, seen in 50% of patients)
- T wave inversions in V1-3 (85% of patients)
- Prolonged S-wave upstroke of 55ms in V1-3 (95% of patients)
- Localised QRS widening of 110ms in V1-3
- Paroxysmal episodes of ventricular tachycardia with a LBBB morphology (RVOT tachycardia)

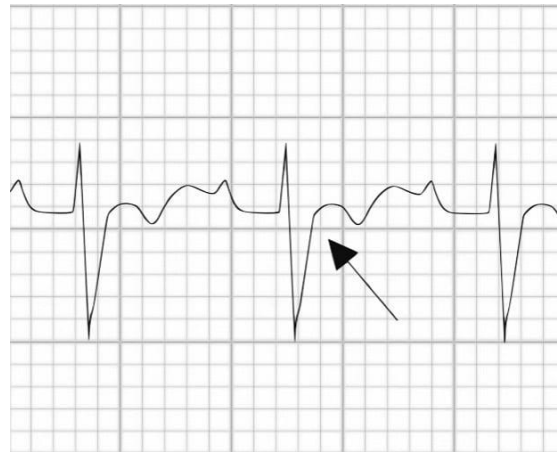
ECG EXAMPLES

Example 1

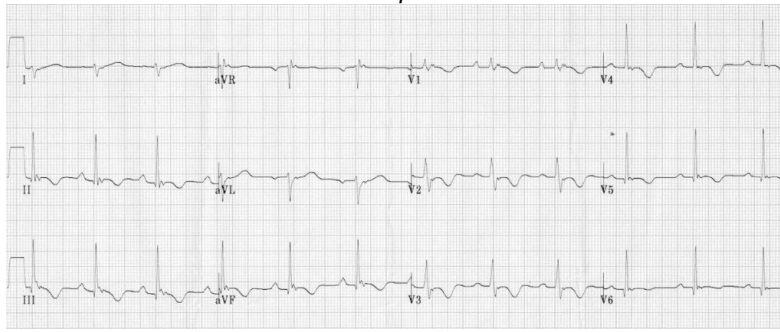

Image: heartpearls.com

- 12-lead ECG is a typical example of ARVD.



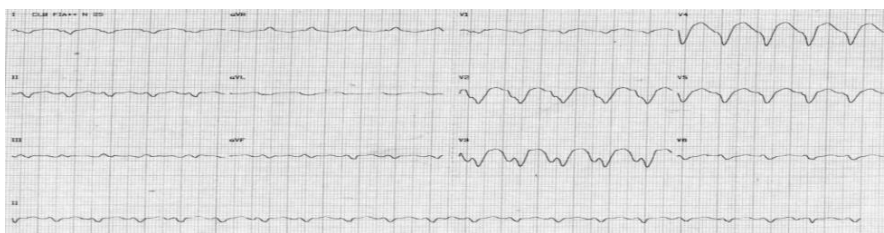
Prolonged S-wave upstroke in ARVD

Example 2

26 year old male presents to emergency with palpitations, dizziness and diaphoresis., No complaints of chest pain or shortness of breath.

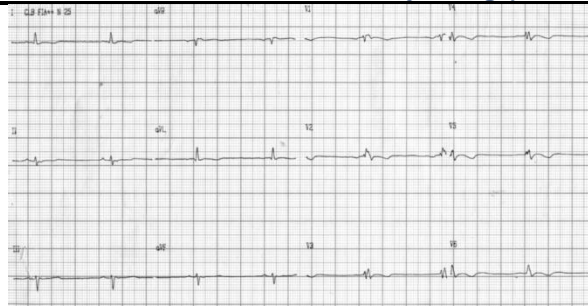
ECG on arrival:

ECG diagnosis: sustained VT with LBBB pattern, heart rate = 125 bpm and right superior QRS axis (only aVR lead with positive



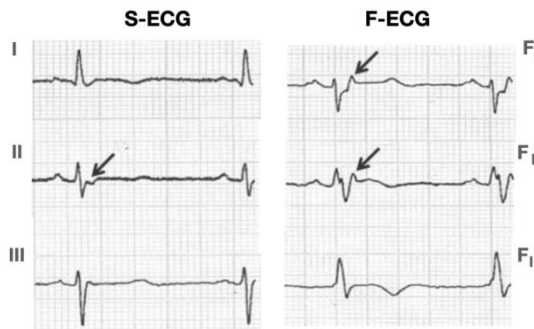
QRS complexes). This atypical axis is a hallmark of VT with focus in apex of right ventricle.

ECG Post cardioversion



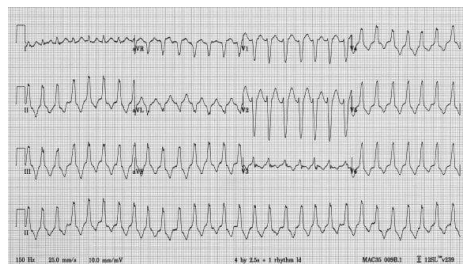
Universal low voltage of QRS complexes. Epsilon wave V2 and lead II. T wave inversion in all precordial leads

F-ECG



Typical example of arrhythmogenic cardiomyopathy with LV involvement. ε wave (arrows). Pérez-Riera AR. 2019

Example 3



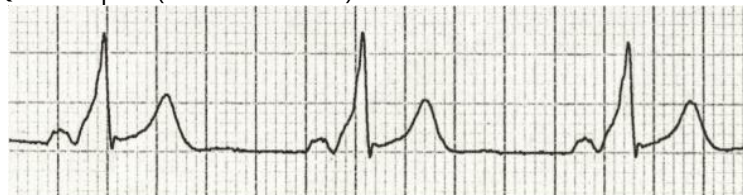
VT with LBBB morphology due to ARVD

Delta Wave Overview

The **Delta wave** is a slurred upstroke in the QRS complex. It relates to pre-excitation of the ventricles, and therefore often causes an associated shortening of the PR interval. It is most commonly associated with pre-excitation syndromes such as WPW.

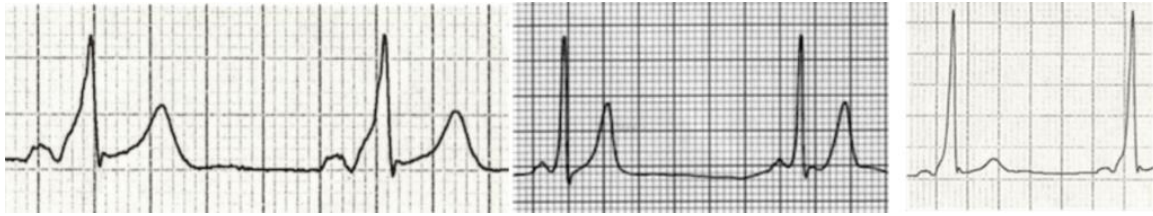
The characteristic ECG findings in Wolff-Parkinson-White syndrome are:

- Short PR interval (< 120ms)
- Broad QRS (> 100ms)
- A slurred upstroke to the QRS complex (the **delta wave**)

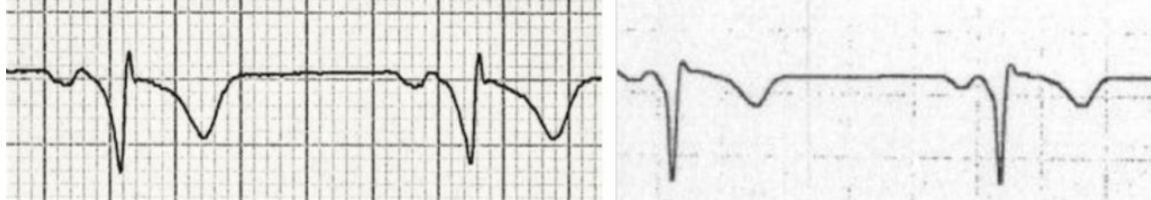


Delta wave: Premature excitation of the ventricles causes a slurred upstroke to the QRS

ECG EXAMPLES OF DELTA WAVES

Delta wave

- Note that the remainder of the QRS remains normal — conduction still occurs through the AV node and this is the dominant pathway. On arrival to the ventricles, such conduction cancels out any pre-excitation that has occurred via an accessory pathway

Negative delta waves (e.g. seen in lead aVR)

- These changes are simply reciprocal to those seen in leads II, aVL, V5 and V6

HISTORY OF THE DELTA WAVE

1930 – Wolff L, Parkinson J, and White PD publish the eleven cases as definitive description of the syndrome – ‘*Bundle Branch Block with Short P-R Interval in Healthy Young People Prone to Paroxysmal Tachycardia.*’ A review of the literature confirmed and acknowledged the previously described cases as above. Wolff, Parkinson, and White *erroneously* thought that the wide QRS complex was caused by a type of bundle-branch block.

ECG Clinical Interpretation**P WAVE****Wide P wave:**

1. Left atrial hypertrophy or enlargement

Tall P wave:

1. Right atrial hypertrophy or enlargement

Small P wave:

1. High nodal rhythm
2. High nodal ectopic
3. Atrial tachycardia
4. Atrial ectopics

Inverted P wave:

1. Nodal rhythm with retrograde conduction
2. Low atrial and high nodal ectopic beats
3. Dextrocardia

Variable P wave morphology:

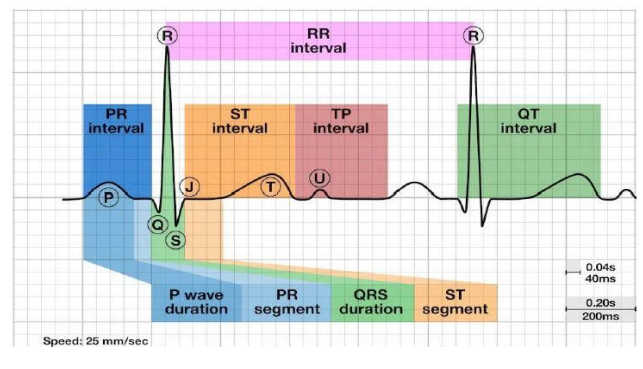
1. Wandering pacemaker

Multiple P waves:

1. Third degree heart block

Absent P wave:

1. Atrial fibrillation
2. Atrial flutter
3. Mid nodal rhythm
4. Ventricular ectopic
5. Ventricular tachycardia
6. Supraventricular tachycardia
7. Idoventricular rhythm
8. Hyperkalemia

**P-R INTERVAL**

Prolonged P-R interval:

First degree heart block Short P-R interval:

1. WPW syndrome. Here delta wave is present.
2. Lown-Ganong-Levin (LGL) syndrome. Here delta wave is absent.
3. Nodal rhythm
4. High nodal ectopic

Variable P-R interval:

1. Mobitz type I heart block (Wenckebach's phenomenon)

R WAVE**Tall R wave in V1:**

1. Right ventricular hypertrophy
2. True posterior MI
3. WPW syndrome
4. RBBB
5. Dextrocardia

Small R wave:

1. Improper ECG standardization
2. Obesity
3. Emphysema
4. Pericardial effusion
5. Hypothyroidism
6. Hypothermia

Poor progression of R wave:

1. Anterior or anteroseptal MI
2. LBBB
3. Dextrocardia
4. Left sided massive pleural effusion
5. COPD
6. Left sided pneumothorax
7. Marked clockwise rotation of heart

Wide QRS Complex (Normal Rate)**I. Intrinsic intraventricular conduction delay (IVCD)***

- A. Left bundle branch block and variants
- B. Right bundle branch block and variants
- C. Other (nonspecific) patterns of IVCD

II. Extrinsic ("toxic") intraventricular conduction delay

- A. Hyperkalemia
- B. Drugs: class I antiarrhythmic drugs and other sodium channel blocking agents (e.g., tricyclic antidepressants and phenothiazines)

III. Ventricular beats: premature, escape, or paced**IV. Ventricular preexcitation: Wolff-Parkinson-White pattern and variants****Low-Voltage QRS Complexes**

1. Artifactual or spurious, e.g., unrecognized standardization of the ECG at half the usual gain (i.e., 5 mm/mV). Always check this first!
2. Adrenal insufficiency (Addison's disease)
3. Anasarca (generalized edema)
4. Cardiac infiltration or replacement (e.g., amyloid, tumor)
5. Cardiac transplantation, especially with acute or chronic rejection
6. Cardiomyopathies: dilated, hypertrophic, or restrictive types
7. Chronic obstructive pulmonary disease
8. Constrictive pericarditis
9. Hypothyroidism/myxedema (usually with sinus bradycardia)
10. Left pneumothorax (mid-left chest leads)
11. Myocardial infarction, usually extensive
12. Myocarditis, acute or chronic

13. Normal variant
14. Obesity
15. Pericardial effusion/tamponade (latter usually with sinus tachycar

Left Axis Deviation (QRS Axis of -30° or More Negative)

- I. Left ventricular hypertrophy
- II. Left anterior (hemiblock) fascicular block (strictly, -45° or more negative)
- III. Inferior wall myocardial infarction (typically with QS waves in leads II, III, and aVF)
- IV. Endocardial cushion defects (congenital), especially ostium primum atrial septal defects

Right Axis Deviation (QRS Axis of $+90^\circ$ or More Positive)

- I. Artifact: left-right arm electrode reversal (look for negative P wave and negative QRS complex in lead I)
- II. Normal variant, especially in children and young adults
- III. Dextrocardia

IV. Right ventricular overload

- A. Acute (e.g., pulmonary embolus or severe asthmatic attack)
- B. Chronic

1. Chronic obstructive pulmonary disease
2. Any cause of right ventricular hypertrophy (e.g., pulmonary stenosis, secundum atrial septal defects, or primary pulmonary hypertension)
- V. Lateral wall myocardial infarction
- VI. Left posterior (hemiblock) fascicular block; note: need to exclude all other causes of right axis deviation and rigorously requires

QT(U) Prolongation (Long QT Syndromes)

I. Acquired long QT syndrome

A. Electrolyte abnormalities

1. Hypocalcemia
2. Hypokalemia
3. Hypomagnesemia

B. Drugs*

1. Class IA or III antiarrhythmic agents (e.g., quinidine, procainamide, disopyramide, dofetilide, ibutilide, sotalol, dronedarone, and amiodarone)
2. Psychotropic agents (e.g., phenothiazines, tricyclic antidepressants, tetracyclic agents, atypical antipsychotic agents, haloperidol)
3. Many others: arsenic trioxide, chloroquine, methadone, certain antibiotics (e.g., erythromycin, levofloxacin, and pentamidine), etc.

C. Myocardial ischemia or infarction (especially, with deep T wave inversions)

D. Cerebrovascular injury (e.g., intracranial bleeds)

E. Bradyarrhythmias (especially high-grade atrioventricular heart block)

F. Systemic hypothermia

G. Miscellaneous conditions

1. Liquid protein diets
2. Starvation
3. Arsenic poisoning

II. Congenital (hereditary) long QT syndromes (LQTS)

A. Romano-Ward syndrome** (autosomal dominant disorders)

B. Jervell and Lange-Nielsen syndrome (autosomal recessive disorder associated with congenital deafness)

Q Waves

I. Physiologic or positional factors

- A. Normal variant septal Q waves
- B. Normal variant Q waves in leads V1, V2, aVL, III, and aVF
- C. Left pneumothorax or dextrocardia (loss of lateral R wave progression)

II. Myocardial injury or infiltration

A. Acute processes

1. Myocardial ischemia or infarction
2. Myocarditis

3. Hyperkalemia
- B. Chronic processes
 1. Myocardial infarction
 2. Idiopathic cardiomyopathy
 3. Myocarditis
 4. Amyloid
 5. Tumor
 6. Sarcoid
- III. Ventricular hypertrophy or enlargement
 - A. Left ventricular hypertrophy (slow R wave progression*)
 - B. Right ventricular hypertrophy (reversed R wave progression**) or slow R wave progression (particularly with chronic obstructive lung disease)
 - C. Hypertrophic cardiomyopathy (may simulate anterior, inferior, posterior, or lateral infarcts)
- IV. Conduction abnormalities
 - A. Left bundle branch block (slow R wave progression*)
 - B. Wolff-Parkinson-White patterns (leads with negative delta waves)

Tall R Wave in Lead V1

- I. Physiologic and positional factors
 - A. Misplacement of chest leads
- B. Normal variants
 - C. Displacement of heart toward right side of chest
- II. Myocardial injury
 - A. Posterior or lateral myocardial infarction
 - B. Duchenne muscular dystrophy
- III. Ventricular enlargement
 - A. Right ventricular hypertrophy (usually with right QRS deviation)
 - B. Hypertrophic cardiomyopathy
- IV. Altered ventricular depolarization
 - A. Right ventricular conduction abnormalities
 - B. Wolff-Parkinson-White patterns (caused by posterior or lateral wall preexcitation)

ST Segment Elevations

- I. Myocardial ischemia/infarction
 - A. Noninfarction, transmural ischemia (Prinzmetal's angina pattern or Takotsubo/stress or apical ballooning cardiomyopathy*)
 - B. Acute myocardial infarction (MI)
 - C. Post-MI (ventricular aneurysm pattern)
- II. Acute pericarditis
- III. Normal variant (benign "early repolarization" and related patterns)
- IV. Left ventricular hypertrophy/left bundle branch block (V1-V2 or V3 and other leads with QS or rS waves, only)
- V. Brugada patterns (right bundle branch block patterns with ST elevations in right precordial leads)
- VI. Myocardial injury (noncoronary injury or infarction)
 - A. Myocarditis (ECG may resemble myocardial infarction or pericarditis patterns)
 - B. Tumor invading the left ventricle
 - C. Trauma to the ventricles
 - D. Acute right ventricular ischemia (usually V1-V2/V3, e.g., with massive pulmonary embolism)
- VII. Hypothermia (J waves/Osborn waves)
- VIII. Hyperkalemia (usually localized to V1-V2)

ST Segment Depressions

- I. Myocardial ischemia or infarction

- A. Acute subendocardial ischemia or non-Q wave myocardial infarction
- B. Reciprocal change with acute transmural ischemia

II. Abnormal noncoronary patterns

- A. Left or right ventricular hypertrophy (“strain” pattern)
- B. Secondary ST-T changes
 1. Left bundle branch block
 2. Right bundle branch block
 3. Wolff-Parkinson-White preexcitation pattern
- C. Drugs (e.g., digitalis)
- D. Metabolic conditions (e.g., hypokalemia)
- E. Miscellaneous conditions (e.g., cardiomyopathy)

III. Physiologic and normal variants*

Tall, Positive T Waves

I. Nonischemic causes

- A. Normal variants (early repolarization patterns)
- B. Hyperkalemia
- C. Cerebrovascular hemorrhage (more commonly, T wave inversions)
- D. Left ventricular hypertrophy
- E. Right precordial leads, usually in conjunction with left precordial ST segment depressions and T wave inversions
- F. Left precordial leads, particularly in association with “diastolic overload” conditions (e.g., aortic or mitral regurgitation)
- G. Left bundle branch block (right precordial leads)
- H. Acute pericarditis (occasionally)

II. Ischemic causes

- A. Hyperacute phase of myocardial infarction
- B. Acute transient transmural ischemia (Prinzmetal’s angina)
- C. Chronic (evolving) phase of myocardial infarction (tall positive T waves reciprocal to primary deep T wave inversions)

Deep T Wave Inversions

I. Normal variants

- A. Juvenile T wave pattern
- B. Early repolarization

II. Myocardial ischemia/infarction

III. Takotsubo (stress; apical ballooning) cardiomyopathy

IV. Cerebrovascular accident (especially intracranial bleeds) and related neurogenic patterns

V. Left or right ventricular overload A. Typical patterns (formerly referred to as “strain” patterns)

B. Apical hypertrophic cardiomyopathy (Yamaguchi syndrome)

VI. Idiopathic global T wave inversion syndrome

VII. Secondary T wave alterations: bundle branch blocks, Wolff-Parkinson-White patterns

VIII. Intermittent left bundle branch block, preexcitation, or ventricular pacing (“memory T waves”)

U WAVE

Prominent U wave:

1. Normally present
2. Hypokalemia
3. Bradycardia
4. Ventricular hypertrophy
5. Hypercalcemia
6. Hyperthyroidism

Q-T INTERVAL

Short QT interval:

1. Tachycardia
2. Hyperthermia
3. Hypercalcemia
4. Digoxin effect
5. Vagal stimulation

Long QT interval:

1. Bradycardia
2. Hypocalcemia
3. Acute MI
4. Acute myocarditis
5. Cerebrovascular accident
6. Hypertrophic cardiomyopathy

7. Hypothermia
8. Hereditary syndrome
 - a. Jervell, Lange-Nielsen syndrome (congenital deafness, syncope and sudden death)
 - b. Romano-Ward syndrome (syncope and sudden death)

Major Bradyarrhythmias

- I. Sinus bradycardia and its variants, including sinoatrial block and wandering atrial pacemaker (WAP)
- II. Atrioventricular (AV) heart block* or dissociation
 - A. Second- or third-degree AV block
 - B. Isorhythmic AV dissociation and related variants
- III. Junctional (AV nodal) and ectopic atrial escape rhythms
- IV. Atrial fibrillation or flutter with a slow ventricular response
- V. Ventricular escape (idioventricular) rhythms

Major Tachyarrhythmias (Basic List, Excluding Artifact)

- I. Narrow QRS complex
 - A. Sinus tachycardia
 - B. Paroxysmal supraventricular tachycardias (PSVTs),* a class of arrhythmias with three major mechanisms:
 1. Atrial tachycardias, including singlefocus or multifocal (e.g., multifocal atrial tachycardia [MAT]) variants
 2. AV nodal reentrant tachycardia (AVNRT)
 3. AV reentrant tachycardia (AVRT) involving a bypass tract
 - C. Atrial flutter
 - D. Atrial fibrillation
- II. Wide QRS complex tachycardias
 - A. Ventricular tachycardia (three or more consecutive premature ventricular complexes at a rate of 100 beats/min)
 - B. Supraventricular tachycardia (including sinus or PSVT), or atrial fibrillation or flutter, with aberrant ventricular conduction usually caused by either of the following:
 1. Bundle branch block (may be rate related)
 2. Atrioventricular bypass tract (e.g., Wolff- Parkinson-White preexcitation pattern)

Wide QRS Complex Tachycardias (More Comprehensive Classification)

- I. Artifact (e.g., tooth-brushing; parkinsonian tremor)
- II. Ventricular tachycardia: monomorphic or polymorphic
- III. Sinus tachycardia, PSVT, or atrial fibrillation/ flutter, with aberrant ventricular conduction, caused by:
 - A. Bundle branch block or other IVCD (may be rate-related)
 - B. Atrioventricular bypass tract (WPW or related preexcitation pattern) with antegrade (top to bottom) conduction over the bypass tract
 - C. Drug toxicity (usually class IC, such as flecainide)
 - D. Hyperkalemia
- IV. Pacemaker-associated
 - A. Sinus or other supraventricular tachyarrhythmia with appropriate pacemaker tracking to upper rate limit
 - B. Pacemaker-mediated tachycardia (PMT)

Atrial Fibrillation: Major Causes and Contributors

1. Alcohol abuse ("holiday heart" syndrome)
2. Autonomic factors
 - a. Sympathetic (occurring during exercise or stress)
 - b. Vagotonic (occurring during sleep)
3. Cardiothoracic surgery
4. Cardiomyopathies or myocarditis
5. Congenital heart disease
6. Coronary artery disease
7. Genetic factors
8. Hypertensive heart disease
9. Idiopathic ("lone" atrial fibrillation)
10. Obstructive sleep apnea (OSA)
11. Paroxysmal supraventricular tachycardias or the Wolff-Parkinson-White preexcitation syndrome
12. Pericardial disease (usually chronic)

13. Pulmonary disease (e.g., chronic obstructive pulmonary disease)
14. Pulmonary emboli
15. Sick sinus syndrome
16. Thyrotoxicosis (hyperthyroidism)
17. Valvular heart disease (particularly mitral valve disease)

Cardiac Arrest: Three Basic ECG Patterns

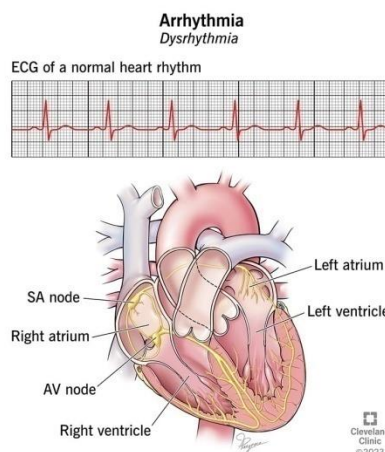
- I. Ventricular tachyarrhythmia
 - A. Ventricular fibrillation (or ventricular flutter)
 - B. Sustained ventricular tachycardia (monomorphic or polymorphic)
- II. Ventricular asystole (standstill)
- III. Pulseless electrical activity (electromechanical dissociation)

Digitalis Toxicity: Major Arrhythmias

- I. Bradycardias
 - A. Sinus bradycardia, including sinoatrial block
 - B. Junctional (nodal) escape rhythms*
 - C. Atrioventricular (AV) heart block,* including the following:
 1. Mobitz type I (Wenckebach) AV block
 2. Complete heart block*
- II. Tachycardias
 - A. Accelerated junctional rhythms and nonparoxysmal junctional tachycardia
 - B. Atrial tachycardia with block
 - C. Ventricular ectopy
 1. Ventricular premature beats
 2. Monomorphic ventricular tachycardia
 3. Bidirectional tachycardia
 4. Ventricular fibrillation

ARRHYTHMIA

An arrhythmia is a heart rhythm that isn't normal. Your heart may be beating too fast when you're at rest or just not beating in a regular pattern, for example. Arrhythmias range from harmless to serious, with symptoms and without. There are many options to treat arrhythmias, but some don't need them. The prognosis varies greatly depending on the type.



An arrhythmia disrupts the way heartbeat signals normally travel through your heart.

What is arrhythmia?

An arrhythmia (also called dysrhythmia) is an abnormal heartbeat. Arrhythmias can start in different parts of your heart and they can be too fast, too slow or just irregular.

Normally, your heart beats in an organized, coordinated way. Issues with various parts of your heart — or even the blood your heart pumps — can affect your heart's normal rhythm. Having a normal heart rhythm matters because your heart supplies your whole body with nutrients and oxygen through the blood it pumps.

How serious is a heart arrhythmia?

Some types of arrhythmia are harmless and don't require treatment. Others can put you at risk for cardiac arrest. Many are in between these two extremes. A healthcare provider can tell you which type of arrhythmia you have and what kind of treatment you need, if any.

What are the types of arrhythmia?

Healthcare providers describe arrhythmias by where in your heart they start.

- **Supraventricular arrhythmias:** These begin in your atria (your heart's upper chambers). "Supraventricular" means above your ventricles or lower chambers of your heart.
- **Ventricular arrhythmias:** These begin in your heart's ventricles or lower chambers.
- **Bradycardias** and **junctional rhythms:** These can happen because of issues in your heart's conduction system, such as the sinoatrial (SA) node, atrioventricular (AV) node or His-Purkinje network.

*Symptoms and Causes**What are the warning signs of arrhythmia?*

- Heart arrhythmia symptoms may include:
- Heart palpitations.
- Dizziness or lightheadedness.
- Fainting episodes.
- Shortness of breath.
- Chest discomfort.
- Weakness or fatigue.

A cardiac arrhythmia may be "silent" and not cause any symptoms.

What causes arrhythmia?

Arrhythmia causes include:

- Coronary artery disease.
- Irritable tissue in your heart (due to genetic or acquired causes).
- High blood pressure.
- Changes in your heart muscle (cardiomyopathy).
- Valve disorders.
- Electrolyte imbalances in your blood.
- Injury from a heart attack.
- The healing process after heart surgery.
- Other medical conditions.

What is the main cause of arrhythmia?

Most arrhythmias happen because of an issue with your heart's arteries, valves or muscles.

What are the risk factors for arrhythmia?

Risk factors for arrhythmia include:

- Using tobacco products.
- Drinking alcohol.
- Consuming drinks and foods that have caffeine.
- Taking stimulants like cold medicines or herbal supplements.
- Having high blood pressure.
- Having a BMI (body mass index) higher than 30.
- Having high blood sugar.
- Having sleep apnea.

What are the complications of arrhythmia?

Without treatment, arrhythmias can lead to complications such as:

- Weakening of your heart muscle (cardiomyopathy).
- Cardiac arrest.
- Stroke.

Diagnosis and Tests

How is an arrhythmia diagnosed?

A healthcare provider can find an irregular heartbeat during an examination by taking your pulse and listening to your heart.

After assessing your symptoms and performing a physical examination, they may order diagnostic tests to help confirm that you have an arrhythmia. This can also help find the cause.

You may also want to see an electrophysiologist — a cardiologist who has additional specialized training in the diagnosis and treatment of heart rhythm disorders.

What tests will be done to diagnose arrhythmia?

Some tests that can check for an irregular heart rhythm and associated diseases include:

- Electrocardiogram (ECG or EKG).
- Blood tests to check your electrolyte levels or look for a genetic issue.
- Ambulatory monitors.
- Stress test.
- Echocardiogram.
- Cardiac catheterization.
- Electrophysiology study (EPS).
- Tilt table test.
- Computed tomography (CT).
- Heart MRI (magnetic resonance imaging).

Management and Treatment

How is an arrhythmia treated?

Treatment depends on the type and severity of your arrhythmia. In some cases, no treatment is necessary. Heart arrhythmia treatment options include:

- Medications.
- Lifestyle changes.
- Therapies.
- Devices.
- Surgery.

Medications

Many medications can treat arrhythmias. Because everyone is different, you may have to try several medications and doses to find the one that works best for you. Heart arrhythmia treatments include:

- Antiarrhythmic drugs that convert the arrhythmia to sinus rhythm (normal rhythm) or prevent an arrhythmia.
- Medicines that control your heart rate.
- Anticoagulant or antiplatelet therapy drugs (such as warfarin or aspirin) that reduce the risk of blood clots forming.
- Medications that treat related conditions that may be causing an abnormal heart rhythm.

It's important to know:

- The names of your medications.
- Why you take them.
- How often and at what times to take them.
- Side effects of your medications.

Lifestyle changes

Simple changes to the way you live can help with arrhythmias. These changes may include:

- Managing blood pressure and blood sugar levels.
- Avoiding tobacco products.
- Cutting back on alcohol intake.
- Avoiding caffeine and stimulants.
- Working toward a healthy weight.

Therapies

In addition to medicine, some people need therapies to treat or eliminate irregular heart rhythms. Your healthcare provider will determine the best treatment for you and discuss the benefits and risks of these therapies with you.

Therapies include:

- **Cardioversion:** An electrical impulse synchronizes your heart and allows your normal rhythm to restart.
- **Catheter ablation:** A catheter sends high-frequency electrical energy to a small area of tissue inside your heart to “disconnect” the abnormal rhythm’s pathway. Ablation can treat most SVTs, atrial flutter, atrial fibrillation and some atrial and ventricular tachycardias.
- **Pulmonary vein isolation:** This type of ablation creates rings of scars to isolate areas that may cause atrial fibrillation. This can help people with frequent, paroxysmal or persistent atrial fibrillation.

Devices

A cardiologist may insert certain devices during a procedure in the electrophysiology lab. Devices to treat a heart arrhythmia include:

- **Permanent pacemaker:** This device sends small electrical impulses to your heart muscle to maintain a normal heart rate and keep your heart from beating too slowly.
- **Implantable cardioverter defibrillator (ICD):** This device constantly monitors your heart rhythm. When it detects a very fast, abnormal heart rhythm, it delivers energy to your heart muscle to make it beat in a normal rhythm. This device treats ventricular tachycardia and ventricular fibrillation, two life-threatening heart rhythms.
- **Biventricular (B-V) pacemakers and defibrillators (also called cardiac resynchronization therapy or CRT):** These devices help to synchronize the contraction of your left ventricle. In addition to the leads that go to the right side of your heart, they have a lead that goes to your left ventricle. People with heart failure and uncoordinated left ventricle contractions may need this.

Surgery

People with arrhythmias may require heart surgery for any of these reasons:

- To treat heart disease that may be causing the arrhythmia, including valve surgery or coronary artery bypass surgery.
- A maze procedure can correct atrial fibrillation that doesn’t respond to medications or nonsurgical treatment methods.
- In some cases, a provider may place biventricular pacemaker leads (tiny wires) on your heart using minimally invasive or surgical techniques.

Complications/side effects of the treatment

Side effects and complications vary depending on the treatment. They may include:

Treatment	Side effects or complications
Arrhythmia medication	<ul style="list-style-type: none"> · Allergic reactions. · Dizziness. · Headaches. · Bleeding. · Upset stomach.
Cardioversion	<ul style="list-style-type: none"> · Embolization of blood clots. · Skin bruises. · Skin rash.
Catheter ablation	<ul style="list-style-type: none"> · Bleeding.

Treatment	Side effects or complications
	<ul style="list-style-type: none"> · Blood clots. · Stroke. · Infection.
Pulmonary vein isolation	<ul style="list-style-type: none"> · Injury to a vein or heart tissue. · Allergic reaction to dye (if used). · Infection. · Injury to your heart, esophagus or vein. · Stroke.
Devices	<ul style="list-style-type: none"> · Device malfunction. · Infection. · Bleeding. · Collapsed lung. · Bleeding. · Infection. · Stroke. · Heart attack. · Need for a pacemaker.
Surgery	<ul style="list-style-type: none"> · Need for a pacemaker.

CARDIAC DISEASES & TERMINOLOGY

A

[Accelerated idioventricular rhythm](#)
[Accelerated junctional rhythm](#)
[Anterior STEMI](#)
[Apical hypertrophic cardiomyopathy \(AHC\)](#)
[Arrhythmogenic right ventricular dysplasia](#)
[Ashman Phenomenon](#)
[Aslanger Pattern \(OMI\)](#)
[Atrial flutter](#)
[Atrial fibrillation](#)
[Atrial ectopic beat / atrial premature beat](#)
[Atrial tachycardia](#)
[Automatic junctional tachycardia](#)
[AV block: 1st degree](#)
[AV block: 2nd degree, Mobitz I \(Wenckebach\)](#)
[AV block: 2nd degree, Mobitz II \(Hay\)](#)
[AV block: 2nd degree, "fixed ratio blocks" \(2:1, 3:1\)](#)
[AV block: 2nd degree, "high grade AV block"](#)
[AV block: 3rd degree \(complete heart block\)](#)
[AVNRT \(AV-nodal re-entry tachycardia\)](#)
[AVRT \(atrioventricular re-entry tachycardia\)](#)
[Axis Interpretation](#)

B

[Belhassen type VT](#)
[Benign early repolarisation](#)
[Beta-blocker toxicity](#)
[Bidirectional VT](#)
[Bifascicular block](#)
[Biventricular enlargement](#)
[Biatrial enlargement](#)
[Brugada syndrome](#)
[Bundgaard syndrome](#)

C

[Calcium-channel blocker toxicity](#)
[Carbamazepine cardiotoxicity](#)
[Cardiomyopathy, dilated](#)
[Cardiomyopathy, hypertrophic](#)
[Cardiomyopathy, restrictive](#)
[Chronic obstructive pulmonary disease \(COPD\)](#)

D

[Delta wave](#)
[De Winter T waves and STEMI](#)
[Dextrocardia](#)
[Digoxin effect](#)
[Digoxin toxicity](#)
[Dilated cardiomyopathy](#)

E

[ECG in Toxicology](#)
[Ectopic atrial tachycardia](#)
[Electrical alternans](#)
[Emphysema](#)
[Epsilon wave](#)
[Escape rhythms, junctional](#)
[Escape rhythms, ventricular](#)

F

[Fascicular VT](#)
[Fusion beats](#)

H

[High take-off](#)
[Hypercalcaemia](#)
[Hyperkalaemia](#)
[Hyperthyroidism](#)
[Hypertrophic cardiomyopathy \(HCM\)](#)
[Hypocalcaemia](#)

L

[Lateral STEMI](#)
[Lead reversals: Limb](#)
[Lead Reversals \(overview\)](#)
[Lead reversal: Left arm/right arm](#)
[Left atrial enlargement](#)
[Left anterior fascicular block](#)

P

[Pacemaker rhythms: Normal pacemaker function](#)
[Pacemaker malfunctions: Failure of capture, pacemaker-mediated tachycardia, etc.](#)

Q

[QRS widening](#)
[QT syndrome – Long \(LQTS\)](#)
[QT syndrome – Short \(SQTS\)](#)
[Quetiapine toxicity](#)

R

[Raised intracranial pressure](#)
[Restrictive cardiomyopathy \(myocardial infiltrative disease\)](#)
[Right atrial enlargement \(RAE\)](#)
[Right axis deviation \(RAD\)](#)
[Right bundle branch block \(RBBB\)](#)
[Right ventricular hypertrophy \(RVH\)](#)
[Right ventricular Infarction](#)
[Right ventricular outflow tract \(RVOT\) tachycardia](#)
[Right ventricular strain](#)
[Romano-Ward syndrome \(LQTS\)](#)
[R-wave peak time](#)

S

[Sgarbossa criteria \(diagnosing AMI in LBBB\)](#)
[Shivering artefact](#)
[Short QT syndrome](#)
[Sinus rhythm](#)
[Sinus arrhythmia](#)
[Sinus bradycardia](#)
[Sinus node dysfunction \(Sick sinus syndrome\)](#)
[Sinus node exit block](#)
[Sinus node reentrant tachycardia](#)
[Sinus pause / arrest](#)
[Sinus tachycardia](#)
[Sodium channel blocker overdose](#)
[South African Flag Sign](#)
[ST elevation in aVR \(LMCA/3VD\)](#)
[STEMI, anterior](#)
[STEMI, high lateral](#)
[STEMI, inferior](#)
[STEMI, lateral](#)
[STEMI \(old\)](#)
[STEMI, posterior](#)
[STEMI, right ventricular](#)
[Subarachnoid haemorrhage](#)
[Supraventricular tachycardia \(SVT\)](#)

0

T

[Tako Tsubo Cardiomyopathy](#)
[Torsades de Pointes](#)
[Tremor artifact](#)
[Tricyclic overdose \(sodium-channel blocker toxicity\)](#)
[Triple vessel disease](#)

W

[Wellens Syndrome](#)
[Wolff-Parkinson White Syndrome](#)

Y

ECG References

ECG References

Electronic Resources

ECG BLOG AND SOCIAL MEDIA RESOURCES

- [Dr Smith's ECG Blog](#)
- [Dr John Mandrola](#)
- [Dr Wes Cardiology Blog](#)
- [EMS 12 Lead](#)
- [Dr John Larkin](#)
- [Dr Ken Grauer](#)

ONLINE ECG RESOURCES

- [ECG Basics](#)
- [ECG Waves](#)
- [ECGpedia](#)
- [Strip Tease](#)
- [Pictorial ECG Primer](#)
- [ECG Learning Center](#)
- [Cardiophile ECG library](#)
- [ECG WAVE Maven](#)
- [The Paediatric ECG](#)
- [12 Lead ECG](#)
- [ECG Library](#)
- [ECG scribbles](#)
- [KCH 100 EKG](#)
- [ECG A to Z by diagnosis](#)

“ABC OF CLINICAL ELECTROCARDIOGRAPHY” SERIES (BMJ)

- [Leads, rate, rhythm, and cardiac axis](#)
- [Basic terminology](#)
- [Bradycardia and AV conduction block](#)
- [Atrial arrhythmias](#)
- [Junctional tachycardias](#)
- [Broad complex tachycardia I](#)

- [Broad complex tachycardia II](#)
- [Myocardial ischaemia](#)
- [Acute myocardial infarction I](#)
- [Acute myocardial infarction II](#)
- [Exercise tolerance testing](#)
- [Right side of the heart](#)
- [Left side of the heart](#)
- [Conditions NOT affecting the heart](#)
- [Paediatric electrocardiography](#)

Paper Resources

BASIC ECG BOOKS

- [The ECG Made Easy](#) by John R Hampton *The classic introductory text to ECG interpretation!*
- [The ECG In Practice](#) by John R Hampton *A great basic ECG text covering all the essentials.*
- [150 ECG Problems](#) by John R Hampton *Test your knowledge with 150 assorted ECGs of varying difficulty.*

ADVANCED ECG BOOKS

- [ECG's for the Emergency Physician 1](#) by Amal Mattu and William Brady *The best ECG book ever published! (except for maybe Part II...) 200 advanced ECG problems covering a wide range of Emergency Department topics, all backed up by great explanations and pearls of wisdom.*
- [ECGs for the Emergency Physician 2](#) by Amal Mattu and William Brady *Another must-have book by the masters of Emergency ECG interpretation. 200 advanced ECG problems to test your mettle.*
- [ECG in Emergency Medicine and Acute Care](#) by T Chan, W Brady, R Harrigan, J Ornato, P Rosen *This is the recommended text for the FACEM and contains a huge amount of information on Emergency ECG interpretation presented in a logical and clinically relevant fashion.*
- [Advanced ECG: Boards and Beyond](#) by Brendan P. Phibbs *This is a more advanced text for those of you wishing to take your ECG interpretation to the next level.*

ECG REFERENCE TEXTS

- [Electrocardiography in Clinical Practice: Adult and Pediatric](#) by Borys Surawicz and Timothy Knilans *The bible of ECG interpretation. Dip into this weighty tome and you will find that it contains the answers to most questions you might have about the humble ECG. Not one to read from cover to cover though!*
- [Marriott's Practical Electrocardiography](#) by Galen S. Wagner *Another comprehensive reference text on ECG interpretation.*