

HOMOEOPATHIC TREATMENT OF *HERPES ZOSTER (SHINGLES)* IN AN ADULT FEMALE- A SINGLE CASE STUDY

Dr. Nidhi Joshi¹, Dr. Arpita Chatterjee², Dr. Mamta Tapas³, Dr. B. P. Panda⁴, Dr. Radha Lathiya⁵

PhD (Scholar) associate professor and HOD FMT Dept, ¹, PhD (Scholar) associate professor and HOD pathology Dept², PhD (Scholar) associate professor in Materia medica Dept³, Principal of Parul institute of homoeopathy and research, professor in Organon of medicine Dept .PhD (scholar)⁴, assistant professor in pathology⁵

PIHR, Parul University, Gujarat, India

Abstract:

Shingles is a painful blistering localised rash that affects typically one side of the body. The most common site for the onset of herpes zoster eruptions is on the torso affecting on one side of the body more. The other common sites are neck, shoulder or face. Post herpetic neuralgia is a common side effect of the disease and sometimes it may lead to vision loss if the eyes are involved with the rashes¹. Shingles is a viral infection caused by the reactivation of the varicella zoster virus. It is found that one third of the population in the world develops this infection at some point in their life. Diagnosis is made easily by clinical examination of the dermatomal pattern of the rash. Homoeopathic system of medicine is a holistic approach towards health based on Similia Similibus Curentur translated it means like cures like. Each individual case is analysed as per its signs and symptoms and the medicine is selected on the basis of symptoms similarity. Rhus Toxicodendron was selected based on symptoms totality and prescribed.

Key word: Shingles, Dermatomal pattern, Homoeopathy, Individualisation, Rhus Toxicodendron

Introduction: -

The varicella-zoster virus produces Herpes zoster and Chickenpox. chickenpox is the acute, primary infection phase of this virus, and herpes zoster (shingles) represents reactivation of virus from the latent phase. It is believed that zoster happens due to the failure of the immune defence system to control the replication of the virus. The prevalence of herpes zoster is strongly correlated to the immune response. The frequency of herpes zoster ranges from 1.2 to 3.4 per 1000 individual per year among more adult healthy persons whereas rate is 3.9 to 11.8 per 1000 people per year among patients older than 65 age. The ailments of herpes zoster include Emotional stress, Use of medications (immunosuppressant), Acute or chronic illness, Exposure to the virus, Presence of a malignancy.

Human herpesvirus-1 and 2 (HHV) have double-stranded DNA and replicate within the nuclei of infected cells. HSV infects mucocutaneous tissue after direct contact or by way of secretions, mainly saliva in the case of HSV-1. The virus is transmitted via sensory nerves to the ganglia, where it may reside in a latent stage. Recurrent infections are caused by reactivation of the virus which travels back to the skin or mucous membranes resulting in an active infection. Immune mechanisms suppress the virus with the clearing of the lesions in 1 to 2 weeks, but latency in the ganglia persists. Recurrent mucocutaneous infection may occur every few weeks to months to years. Viral shedding may continue after the infection has clinically resolved.

This condition having certain specific symptoms, they are a rash, vesicles on an erythematous base. Mainly they are seen on one or more adjacent dermatomes in the thoracic or lumbar region, although a few satellite lesions may also appear. The lesions are typically unilateral. Lesions usually continue to form for about 3 to 5 days. The pain is more severe.

In homoeopathy treatment is based on individualization of a case. In herpes cases many medicines works well and they are indicated in many cases depend upon symptoms totality. Medicines like Rhus. Tox., Ars. Alb., Graphites., Petroleum, Nat. Mur, etc. Let us learn about these disease condition with one of the cases which was treated with homoeopathic medicine on base of individualization of the case.

CASE OF HERPES SHINGLES

Case History: -

A female patient aged 32yrs old, by occupation a soft skill trainer visited on 10th Feb 2020 at the outpatient department. She had come with the complaints of small red vesicular eruptions on the neck and the supraclavicular area of the skin. The eruptions were accompanied with severe pain & burning sensation. She also complained of stiffness of neck since 2days.

LIFE SPACE INVESTIGATION: -

Patient belong to middle class family. Her father is an ex-defence personnel and her mother is a house wife. She has an elder sister who is a health care work. She has been working since the age of 17 years and studying as well. She is a soft skill trainer and does freelancing in different institutes. She is intelligent, opinionated and strong person. She is a hot patient and perspiration is profuse. She has a desire for ice creams and chocolates. Her appetite, urine and stool is normal. She is at present restless, irritated due to the complaints and has pain around the neck with stiffness. She feels very tired and weak.

PRESENTING COMPLAINTS:

Since last 2days she was having pain and redness below the clavicle on the right side. After 2days she developed small vesicular eruptions on the right side of the neck and around the clavicle. Mild fever and weakness, remains sad, not interested even in regular activities, feels irritated. Feeling very lonely, doesn't want to speak even family members, friends, becomes restless. Feels very weak during day time with much more fatigue. Disturbed sleep at night due to the pain and stiffness in the neck. Difficult in moving the shoulder on the right side and turning head causes severe pain with burning sensation.

PAST HISTORY: She had chicken pox at the age of 6yrs. History of malaria when she was 10yrs of age. She had suffered from mumps 6-7yrs back. She had suffered from Hepatitis E 10years back. She has PCOD for which she takes homoeopathy and, in the past, had hypothyroidism which was cured with homoeopathy 6 years back. No other any major illness in past.

FAMILY HISTORY: Father is having no complains. Mother is a known case of pulmonary hypertension and diabetes in the last 9 year.

- Dominant miasm: sycosis miasm (Herpes zoster has a sycotic base. - H.A. Robert)
- Fundamental miasm: sycosis miasm

PERSONAL HISTORY:

- In general physicals Patient is averagely built & nourished.
- Desire for chocolates and ice creams++
- Thirsty ++for large quantity constipation with soft stool mixed diet
- Sleep is disturbed
- No pallor or oedema

GENERAL PHYSICAL EXAMINATION:

- Fair complexion medium built
- Weight- 65 kg
- Height-167 cm
- Anaemia-nil
- Jaundice-nil
- Cyanosis-nil
- Generalized lymphadenopathy- nil
- Pulse-84/min
- BP-120/80 mmHg
- Temperature-98.7F
- Respiratory rate- 16/min
- Diagnosis – Herpes shingles

MENTAL GENERALS:

- Sad,
- Feeling very lonely,
- doesn't want to speak even family members or friends.
- Irritable
- Restless

SYSTEMIC EXAMINATION: Respiratory System- NAD, Cardiovascular System- NAD, Gastro-intestinal System-NAD, Locomotors System- NAD

IN THIS CASE SYMPTOMS CONSIDERED FOR REPERTORIZATION:

- Irritability
- Desire for sweets
- Sleep is disturbed
- Physical Restlessness.
- Vesicular eruptions
- Burning sensation
- Lack of body heat
- Pain in the neck
- Stiffness of the neck

Homoeopathic Medicinal management, Follow up and Outcome: Selection of medicine:

Reportorization was done using Radar 10.0 giving priority to mental generals then physical generals then particular symptoms. After repertorisation, the main remedies that can be considered are Rhus tox- 9²⁵, Calc- 6¹³, Phos-6¹⁰, Sulph- 5¹⁰, Ars Alb- 5⁹ which covers majorities of symptoms.

Rhus tox: Herpetic eruption, with incessant itching, burning, and tingling, alternating with pains in chest and dysenteric stools; burning and stinging herpes upon hairy parts, more annoying after a perspiration. Herpes Zoster. Herpes zoster—zona, " shingles"—is a common and interesting disease, especially for its connections with nerve-pathology. It has been treated homeopathically by many remedies, but I hardly think we need go so far afield. When occurring in young or middle-aged persons, I have always treated it with Rhus. It is said by dr. Richard huges.

Calc carb: Burning herpes; chapped purpuraceous eruptions; unhealthy skin, which ulcerates easily, worse in open air and from water, better in warm room.

Phos: Herpes in persons inclined to pulmonary difficulties, with burning pain; vesicles confluent and appear in clusters; brown-colored blisters between the fingers and toes; restlessness, wants to change position, worse before midnight, exceedingly sensitive to cold air, better after sleeping

Sulph: Herpes, with great itching, burning, and soreness after scratching; herpes about nose and mouth; face pale and colorless, lips bright red; aversion to water and open.

Ars. Alb: Confluent herpetic eruptions, with intense burning of the blisters; cannot sleep after midnight; chronic dry skin; nausea and marked prostration, lassitude, and weakness, worse from cold of any kind, better from warmth. Herpes having a red unwholesome appearance.

These are the symptoms of each medicine which ranking in the reportorization. Majority of it are polycrest. On the basis of totality of symptoms, we have to select medicine which cover majority of symptoms.

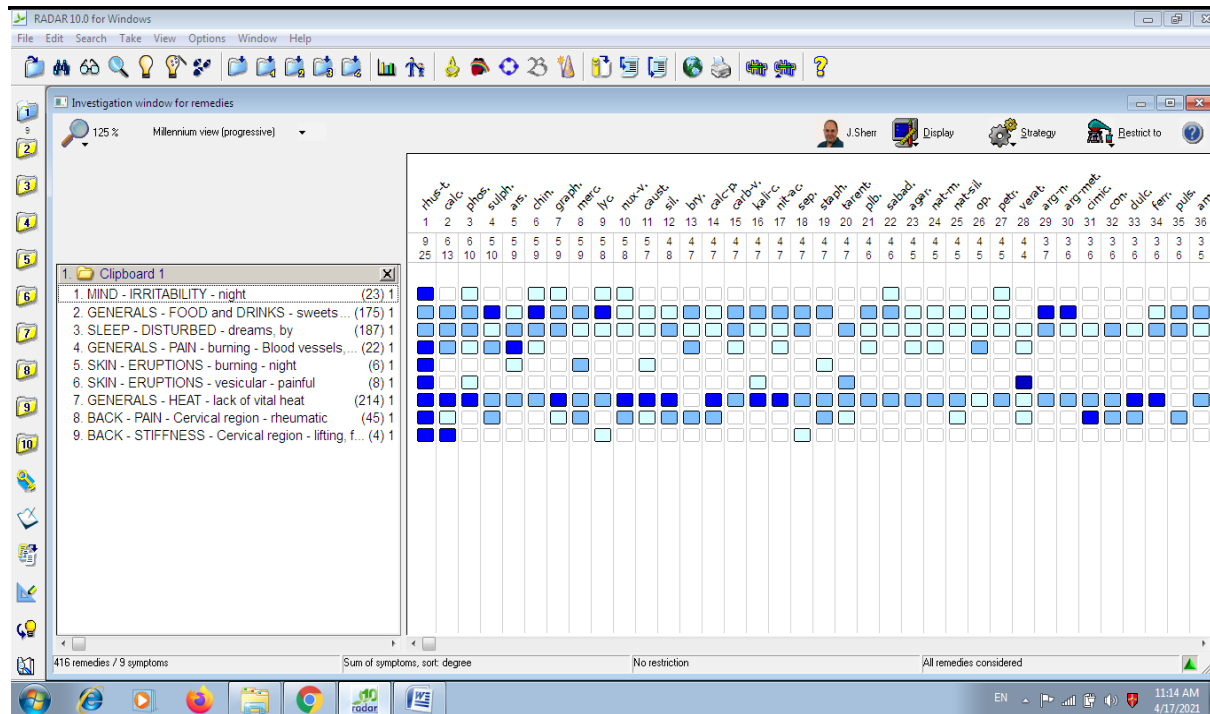
PRESCRIPTION:

Table-1: timeline and follow up

Date	Observation	Medicine with doses and repetition
21/7/2020	She is feeling Irritability, Desire for sweets. Her Sleep is disturbed, she is Physically Restless. On her skin Vesicular eruptions, she is having Burning sensation. Pain in the neck. Stiffness of the neck.	Rhus Tox 30 was given thrice a day for 2days. Advised to have nutritious diet, plenty of fluids and complete rest.
23/7/2020	Irritability is reduced by 20%, according to family members she is slowly coming out of sadness.	Rhus Tox 30 twice repeated & ask to come after 2 days.
26/7/2020	Looks quite fresh, no pain or stiffness, smile on face, Sleep is improved.	S. L. (sac lac)/twice a day/2 day
31/7/2020	80% improvement. She is looking very happy, no weakness, rarely gets depression.	S. L. (sac lac)/twice a day/2 day
03/8/2020	She is happy, no other complaints. There is light blackish discoloration around the neck and the clavicle area. Sound sleep.	S. L. (sac lac)/twice a day/7 day

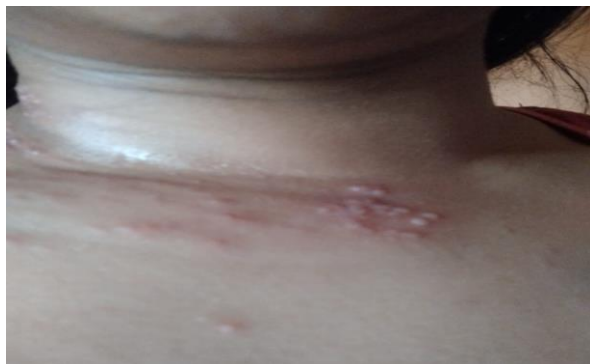Table 2: Assessment According to Modified Naranjo criteria:

No	Questions	Yes	No	Not sure or N/A	Scores
1.	Was there an improvement in the main symptom or condition for which the homeopathic medicine was prescribed?	yes			+2
2.	Did the clinical improvement occur within a plausible timeframe relative to the drug intake?	yes			+1
3	Was there an initial aggravation of symptoms?		no		
4	Did the effect encompass more than the main symptom or condition, i.e., were other symptoms ultimately improved or changed?	yes			+1
5	Did overall well-being improve?	yes			+2
6A	Direction of cure: did some symptoms improve in the opposite order of the development of symptoms of the disease?		no		0
6B	Direction of cure: did at least two of the following aspects apply to the order of improvement of symptoms: <ul style="list-style-type: none"> • from organs of more importance to those of less importance? • from deeper to more superficial aspects of the individual? • from the top downward? 		no		0
7	Did “old symptoms” (non-seasonal and non-cyclical symptoms that were previously thought to have resolved) reappear temporarily during the course of improvement?		no		
8	Are there alternate causes (other than the medicine) that solely could have caused the improvement? (e.g., known course of disease, other forms of treatment and other clinically relevant intervention)		no		
9	Was the health improvement confirmed by any objective evidence?	yes			+2
10	Did repeat dosing, if conducted, create similar clinical improvement?	yes			+1

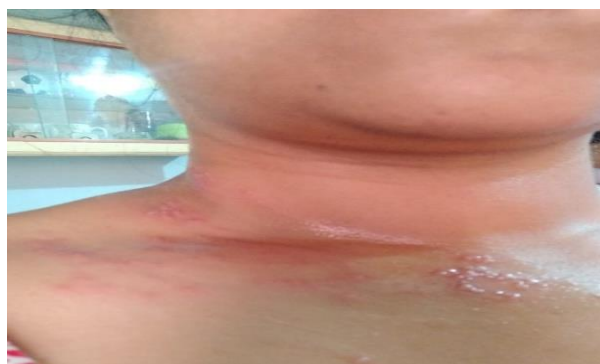

Before

21/07/2020

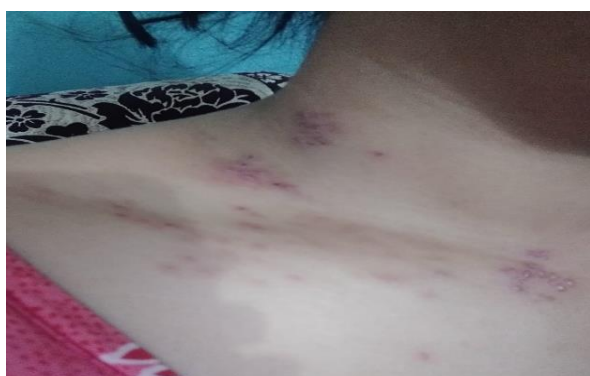

21/07/2020

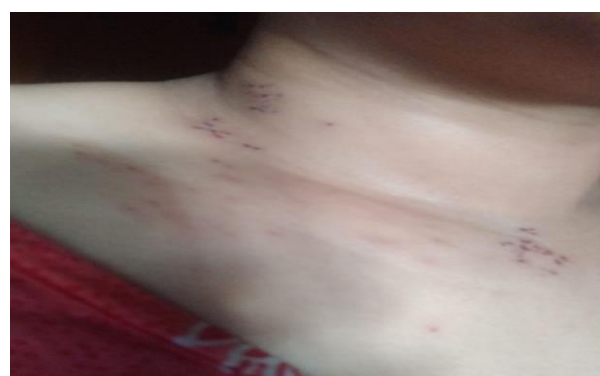

After

26/07/2020



31/07/2020



Discussion: -

In homoeopathy every case is unique and need treatment on base of individualization. This acute viral herpes zoster infection was cured successfully with only homoeopathic medicine. The post herpetic neuralgia was absent after the infection was subdued. This case is unique as it shows the efficacy of homoeopathic medicine in viral infection and the duration of the disease is also shorten with our medicine. In this case a 32yrs old female working women had developed shingles. She was restless and mentally depressed with the condition. There were small eruptions on the right side of the neck and along the clavicle with severe pain, burning sensation and stiffness of the neck. The selection of the medicine was based on the principle of individuation,

single medicine and minimum dose as per the guidelines laid in organon of medicine. Depending on the susceptibility of the patient the potency selection was done. Here as it was an acute disease and symptoms were few which mostly consisted of common symptoms of the disease hence low potency and frequent repetition was done. The reduction in the pain and stiffness of the neck in 3 days proved the positive effect of constitution remedy in homoeopathy. The non-occurrence Postherpetic neuralgia (PHN) in this case after the discontinuation of the medicine is highly remarkable. The mental state of the patient had also improved she was feeling fresh, happy and active in just 5 days without any antiviral or pain killers or anti-inflammatory. This shows the holistic approach that the homoeopathic medicine has on the health of the patient further it also shortens the duration & phase of the acute disease. The observed result was very satisfactory in the case. This however points to the fact the evaluation of symptoms is the key factor in homoeopathic prescription. The evaluation helps to judge which symptoms to rank at which place.

The modified Naranjo Criteria was applied for the assessment of the casual attribution that were seen in the patient's clinical state after therapeutic intervention. The patient's total score was 9. Based on this score of Madified Naranjo Criteria it can be said thus concluded that there is definite relation between the patient clinical state and the treatment provided. [Definite ;>9, probable: 5-8, possible; 1-4 and doubtful <0.] (Table-2)

Conclusion:

Shingles is the viral disease that is characterized by rash and vesicular eruptions on the torso, neck and face and is followed by severe neuralgia with post herpetic pain. In adults it is a reactivation of the varicella zoster virus due to poor immunity, diseased condition or old age. Individualized homoeopathic medicine enhances the immunity and general health of the patient. Cost and care are comparatively very economical and it also promises complete recovery with no post herpetic neuralgia or other complications. The recovery is faster and the sense of wellbeing in the patient is achieved without pain killer. If detail case taking, proper analysis, & reportorization is done we can give complete improvement to the patient with Homoeopathy without any side effects.

Informed consent: -

The authors certifies that the patient completed a consent form in which she gave her consent for her medical images and other clinical information to be reported anonymously in an academic journal. She was informed that it would be published without revealing her identity.

Reference:

1. [Shingles | Signs and Symptoms | Herpes Zoster | CDC \(archive.org\)](#) [last accessed on 17th may 2021]
 - <https://en.wikipedia.org/wiki/Shingles#Diagnosis>
 - Lilienthal s., homoeopathic therapeutics, second, revised, and enlarged edition, sherman & co., printers and stereotypers, Philadelphia.
 - Hughes Richard, a manual of therapeutics according to the method of Hahnemann, second edition - mainly re-written, London.
 - <https://www.msmanuals.com/professional/infectious-diseases/herpesviruses/herpes-zoster#v1019800>
 - [red](#)
 - <https://www.ncbi.nlm.nih.gov/books/NBK441824/>
 - [purple](#)